

The Identification of a Novel Compound Heterozygous Mutation in Hereditary Human Coagulation Factor VII (FVII) Deficiency Following a Bamboo Leaf Green Snake Bite

Chuanghua Qiu ¹, Chunxiu Huang ¹, Xueyan Chen ², Dayong Gu ^{1*}

¹ Department of Laboratory Medicine, Shenzhen Second People's Hospital, Shenzhen, China.

² Clinical Laboratory, Department of Clinical Laboratory, The People's Hospital of Longhua Shenzhen, Shenzhen, China.

*Corresponding Author: Dayong Gu, Department of Laboratory Medicine, Shenzhen Second People's, Hospital Shenzhen, China.

Received Date: February 06, 2024 | Accepted Date: February 23, 2024 | Published Date: February 28, 2024

Citation: Qiu C., Huang C., Chen X., Gu D., (2024), The Identification of a Novel Compound Heterozygous Mutation in Hereditary Human Coagulation Factor VII (FVII) Deficiency Following a Bamboo Leaf Green Snake Bite, *Journal of Clinical and Laboratory Research*. 6(3); DOI:10.31579/2768-0487/121

Copyright: © 2024, Dayong Gu. This is an open-access article distributed under the terms of the Creative Commons Attribution License, which permits unrestricted use, distribution, and reproduction in any medium, provided the original author and source are credited.

Abstract

Hereditary factor VII (FVII) deficiency is an uncommon autosomal recessive disorder associated with mutations in the F7 gene and laboratory investigations usually reveal isolated prolongation in prothrombin time (PT)/International normalized ratio (INR). Venom-induced consumptive coagulopathy (VICC) is distinguished by the activation of the coagulation pathway, which is triggered by procoagulant toxins in snake venom. Diagnosing snakebites in patients with hereditary FVII deficiency presents a challenge due to the fact that prolonged time PT/INR is considered the most valuable diagnostic method for VICC. Therefore, it is possible that certain patients may not promptly receive an accurate diagnosis of hereditary FVII deficiency. We present a pedigree featuring hereditary FVII deficiency, which was diagnosed through Sanger sequencing, following a bamboo leaf green snake bite.

Key words: hereditary factor VII (FVII) deficiency; venom-induced consumptive coagulopathy (VICC); gene mutation, pedigree analysis

1. Introduction

Coagulation FVII is a plasma vitamin K-dependent serine protease that is solely synthesized in the liver and its concentration in the bloodstream is approximately 0.5µg/ml. FVII(F7) gene, which is situated on chromosome 13q34, comprised a total of 9 exons [1]. FVII is a distinct coagulation factor that exhibits a minor portion (1%–3%) of its activated form (FVIIa) in the blood, even in the absence of coagulation activation [2]. A minute quantity of FVIIa can effectively initiate the process of coagulation.

Coagulopathy is a prevalent outcome of snake bites, with venom-induced consumptive coagulopathy (VICC) being the most critical manifestation of this condition [3]. VICC is distinguished by the activation of the coagulation pathway, which is triggered by procoagulant toxins in snake venom. They are referred to as procoagulant toxins due to their ability to induce rapid clot formation in vitro and cause significant consumption of factors in vivo, leading to a potential risk of bleeding [4]. Hereditary FVII deficiency stands as the most prevalent among the rare autosomal recessive bleeding disorders, which is often referred to as a “chameleon disease” due to the absence of a

clear association between plasma FVII levels and bleeding symptoms [5]. Diagnosing hereditary FVII deficiency becomes particularly challenging in cases of snakebite envenoming, due to the fact that the prothrombin time (PT)/International normalized ratio (INR) is considered the most valuable diagnostic method for VICC. Therefore, it is possible that certain patients may not promptly receive an accurate diagnosis of hereditary FVII deficiency.

In this report, we present a pedigree featuring hereditary FVII deficiency in a 2-year-old boy who exhibits markedly low FVII activity and subsequently establish a diagnosis of the hereditary compound heterozygous FVII deficiency through Sanger sequencing, following a bamboo leaf green snake bite. The results revealed that the proband, who had severe FVII deficiency, identified compound heterozygosity for c. T1224G and c.G1034T mutations in the F7 gene, leading to p. His408Q and p. Gly345Val, respectively. One of these heterozygous variants c. G1034T: p. Gly 345Val was first reported.

2. Case presentation:

A 2-year-old boy presented to the hospital with swelling and pain in his left foot, caused by a bite from a bamboo leaf green snake one day ago. Upon examination, there was noticeable bruising on the dorsal surface of the left foot without any signs of necrosis or fever present. The patient was promptly treated with antivenom neutralization of toxin, dexamethasone sodium phosphate for inflammation, azithromycin for infection, and furosemide for

diuresis. During hospitalization, he exhibited normal health conditions with the exception of an abnormal coagulation profile, especially markedly prolonged PT/INR. Hence, it cannot be ruled out that the patient might have experienced concurrent venom-induced consumption coagulopathy (VICC). One month after being discharged, there was no longer any noticeable swelling and pain at the site of the snakebite. However, the value of PT/INR was still significantly higher than the upper reference range (Figure 1).

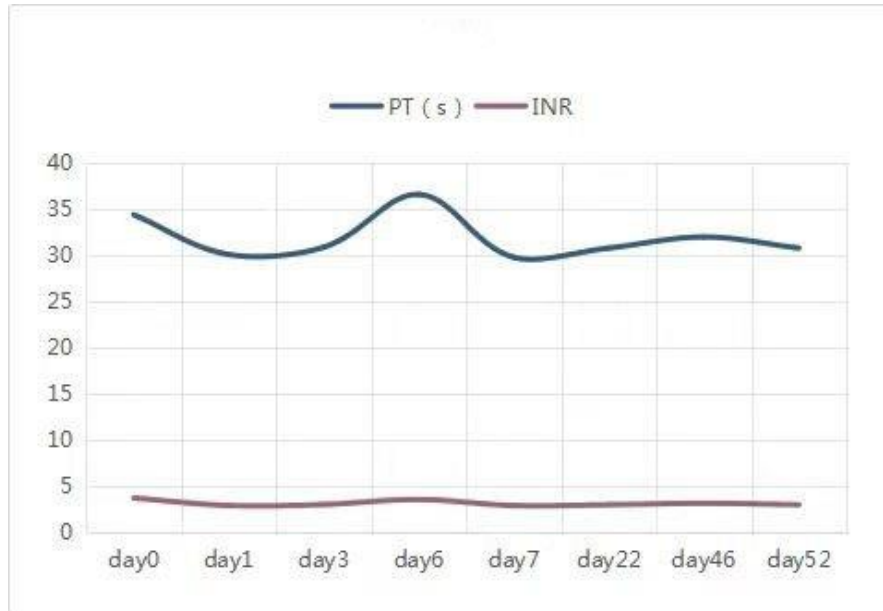


Figure 1: Demonstrates that the prothrombin levels in the proband did not return to normal until 52 days following the snake bite.

Further coagulation activities of the plasma FVII (FVII: C) assays confirmed that plasma FVII level was below 3% (normal range 70%-120%). Detection FVII: Ag by enzyme-linked immunosorbent assay (ELIAS) also showed a marked reduction. The mixing studies effectively restored the PT/INR to the

normal range, suggesting a significant probability of a coagulation factor VII (FVII) deficiency. Meanwhile, his parents showed no abnormalities in the coagulation profile. The coagulation profile of the family is presented in Table 1.

Family members	PT (s)	INR	APTT (s)	TT (s)	FIB (g/L)	DD (mg/L)	FVII:C (%)	FVII: Ag (%)	FII:C (%)	FX:C (%)	FIX:C (%)
Father	13.0	1.08	29,8	18.1	2.1	0.42	80	78.3	NA	NA	NA
Mother	12.8	1.07	31.2	18.3	2.3	0.45	73	81.2	NA	NA	NA
Proband	30.0	2.67	30.6	17.9	2.17	17,8	3	19.3	104	119	71
Normal range	10-14	0.8-1.2	28-44	14-21	2-4	<0.5	70-120	80-120	70-120	70-120	70-120

Abbreviations: INR, International standardized ratio of prothrombin; PT, prothrombin time; APTT, activated partial time; FIB fibrinogen; TT, thrombin time; DD, D – dimer.

Table 1: Coagulation profile in the family members

Following the parent’s written informed consent, blood samples were collected for molecular testing and to establish an underlying genetic cause for coagulation factor VII (FVII) deficiency. Genomic DNA was extracted from the peripheral blood samples of all family members and all nine exons of FVII were analyzed using polymerase chain reaction (PCR) followed by next-generation sequencing at the Guangzhou Zhili Medical Laboratory. The PCR products that were sequenced and the corresponding GenBank sequences (NM_000131) were analyzed in order to identify the sites of

mutation. The finding revealed that the proband exhibited a missense mutation (heterozygous) in exon 9 of the F 7 gene (c.T1224G, p. His 408 Q) was inherited from his mother and a missense mutation (heterozygous) in exon 9 of the F 7 gene (c. G1034T: p. Gly 345Val) was inherited from his father (Figure 2-3). No additional mutations were detected in the exons of the F7 gene. The proband was finally identified as a compound heterozygous carrier of the c.T1224G, p. His 408 Q and the c. G1034T: p. Gly 345Val mutations.

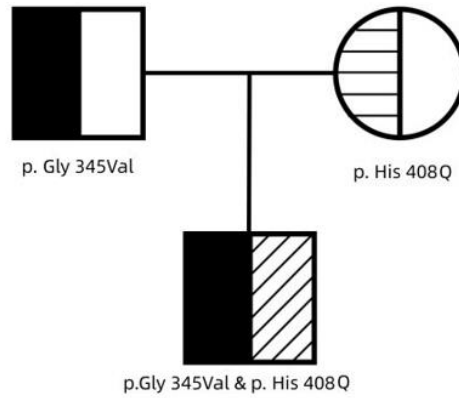


Figure 2: Pedigree of the family

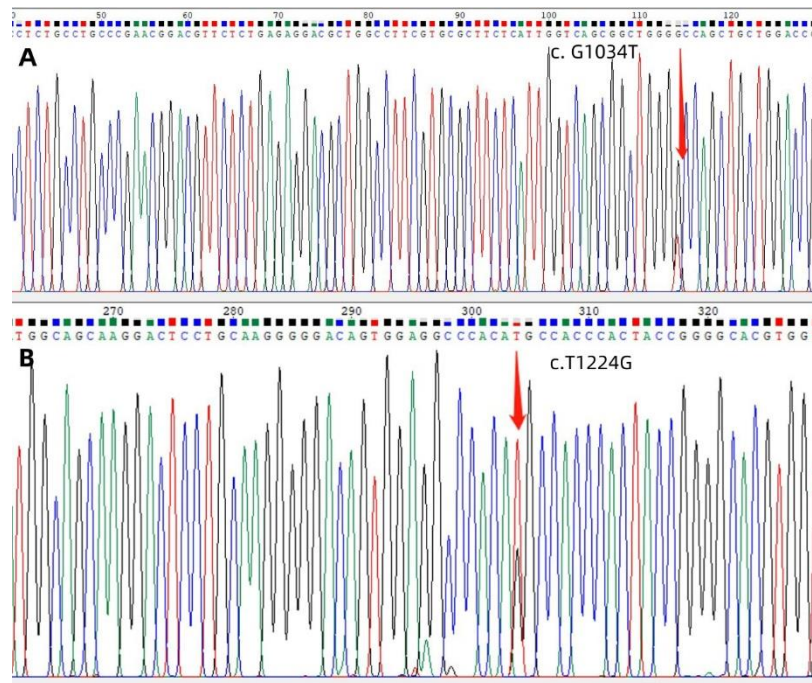


Figure 3: The Sanger sequencing revealed the presence of mutations in exon 9 of the F7 gene in pedigree. The mutation site c. G1034T was identified from the father, as shown in Panel A; Panel B displayed the mutation site c.T1224G from the mother.

Based on the reported data from <http://www.factorvii.org> [6], it is evident that the heterozygous mutation p. His 408 Q has already been reported, with a frequency of 0.0004 in East Asian populations. According to the American College of Medical Genetics and Genomics (ACMG) guidelines, the heterozygous mutation p. Gly 345Val has not been previously reported. All of the aforementioned mutations are disease-causing.

3. Discussion

There are three conditions that can contribute to diagnosing FVII deficiency: laboratory tests conducted following bleeding episodes, screening within the scope of a family of FVII deficiency (when at least one family member carries a mutation), or incidental findings [7]. The median age at which the genetic defect was identified was 8 years [7].

FVII deficiency is readily suspected when the coagulation profiles reveal an isolated prolongation of PT and a normal activated partial thromboplastin time (aPTT), in conjunction with normal liver function [8]. To ensure the exclusion of transient or combined defects, it is recommended to draw

samples a few weeks after the initial test and repeat the testing process for the confirmation of any congenital defects [9].

Extensive research studies conducted with clinical inquiries and encompassing extensive patient cohorts have significantly enhanced our comprehension of disease manifestation and diagnosis. Hereditary FVII deficiency presents a broad range of clinical manifestations, spanning from mild mucocutaneous bleeding (resembling platelet disorders) to potentially life-threatening bleeding, such as central nervous system (CNS) and gastrointestinal (GI) bleeding [10]. Approximately one-third of patients with deficiency typically remain asymptomatic throughout their lifetime [11].

The presentation of bleeding in FVII deficiency is highly variable, both in terms of location and severity. There is no direct correlation between FVII activity (FVIIa) and clinical findings [1]. In other words, the bleeding tendency in severely affected homozygotes or compound heterozygotes exhibits variability and does not consistently align with highly reduced FVII activity [10]. Therefore, the routine coagulation laboratory work-up, including PT and FVII levels based on PT is insufficient for actually

assessing the risk of bleeding. This scenario was also observed in our patient, presenting significantly abnormal laboratory results, yet lacking abnormal clinical findings. The aforementioned results suggested that a minute quantity of FVIIa, even below 3%, can effectively initiate the process of coagulation and protect from bleeding. The unpredictability of this behavior could possibly be attributed to the cumulative potentiation of the TF- FVII complex [12]. A complete absence of FVII has been observed to be correlated with life-threatening bleeding conditions in newborns [13]. However, a documented history of experiencing severe bleeding has been reported in patients with FVII: C levels above 5% [14]. The reason for the absence of a correlation between clinical and laboratory phenotypes remains unclear.

Whole gene sequencing (WES) is the preferred method for the genetic diagnosis of FVII deficiency. A small portion of the patients with FVII

deficiency, less than 10%, do not identify any mutations using DNA sequencing. This could potentially be associated with a mutation in another gene [15]. Patients who shared the identical homozygous or compound heterozygous mutation did not consistently fall under the same severity classification, suggesting the existence of phenotypic diversity in the presence of the shared FVII mutations [16]. The structural analysis strongly reinforces the clinical findings, as it accurately predicts the presence of a structural defect that interferes with the function of the protein and causes a reduction in both FVII antigen and activity in plasma.

We conducted a thorough structural prediction analysis of the patient's mutated FVII protein. The green shape represents the normal protein, while the blue shape represents the mutated forms p. (Gly 345Val) and p. (His 408 Q) with valine and glutamine, respectively (Figure 4).

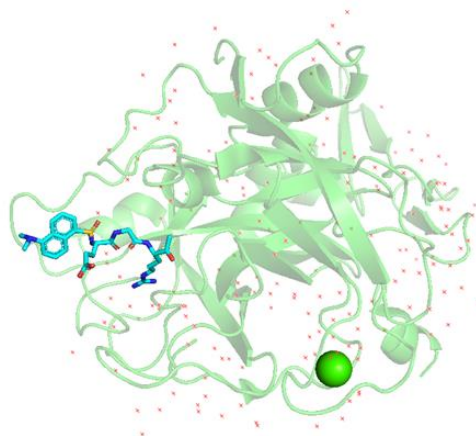


Figure 4: The figure displays the mutated protein derived from the PDB database with the purpose of identifying the structure of the factor VII (F7) protein. Especially, it represents the crystal structure of the active site-inhibited human coagulation factor VIIa (DES-GLA), available on RCSB PDB - 1CVW. Both mutations of the case were visualized on PyMOL. The normal protein was represented in green, while the mutated forms G1034T(Gly345Val) and T1224G (His 408Q) were displayed in blue. The mutated Valine and Glutamine were clearly visible in their respective positions.

Together with clinical presentation, laboratory work-up, and genetic findings, we report a novel compound heterozygous mutation, the heterozygous missense mutations of c.T1224G, p. His 408 Q and c. G1034T: p. Gly 345Val both in exon 9 of the F7 gene. These mutations potentially contribute to the congenital FVII defect in this family, suggesting a change in the molecular spatial conformation of the FVII domain.

4. Conclusion

We report a novel compound heterozygous mutation, the heterozygous missense mutations of c.T1224G, p. His 408 Q and c. G1034T: p. Gly 345Val both in exon 9 of the F7 gene. The identification of coagulopathy in a patient who has recovered from a snake bite is a significant diagnostic indicator for the presence of congenital coagulopathy.

Conflict of interest:

There is no conflict of interest relevant to this paper to disclose.

Reference

- Mariani, G; Bernardi, F. (2009). Factor FVII Deficiency. *Semin. Thromb. Hemost.* 35, 400-406.
- Rapaport, S.I.; Rao, L.V. (1995). The tissue factor pathway: How it has become a "prima ballerina". *Thromb. Haemost.* 74, 7-17.
- Maduwage, K.; Isbister, G.K. (2014). Current treatment for venom-induced consumption coagulopathy resulting from snakebite. *PLoS Negl. Trop. Dis.* 8, e3220.
- Berling, I.; Isbister, G.K. (2015). Hematologic effects and complications of snake envenoming. *Transfus. Med. Rev.* 29, 82-89.
- Mariasanta N.; Sergio S.; Guglielmo M. (2017). Factor VII Deficiency: Clinical Phenotype, Genotype, and Therapy. *6(4):38.*
- Giansily-Blaizot, M., Rallapalli, P. M., Perkins, S. J., Kemball-Cook, G., Hampshire, D. J., et al. (2020). The EAHAD Blood Coagulation Factor VII Variant Database. *Human Mutation*, 41, 1209-1219.
- Pierre-Olivier S.; Daniel Ak.; Francois D. (2017). Factor VII Deficiency: From Basics to Clinical Laboratory Diagnosis and Patient Management. *Clinical and Applied Thrombosis/Hemostasis.* 23(7):703-710.
- K. Sue Robinson. (2019). An overview of inherited factor VII deficiency. *Transfus Apher Sci.* 58(5):569-571.
- Napolitano, M.; Mariani, G.; Lapecorella, M. (2010). Hereditary combined deficiency of the vitamin K-dependent clotting factors. *Orphanet. J. Rare Dis.* 5, 21.
- Perry, D.J. (2022). Factor VII Deficiency. *Br. J. Haematol.* 118, 689-700.
- Mariani, G.; Herrmann, F.H.; Dolce, A.; Batorova, A.; Etro, D.; et al. (2005). Clinical phenotypes and factor VII genotype in

- congenital factor VII deficiency. *Thromb. Haemost.* 93, 481–487.
12. Monroe, D.M.; Key, N.S. (2007). The tissue factor-factor VIIa complex: Procoagulant activity, regulation, and multitasking. *J. Thromb. Haemost.* 5, 1097–1105.
 13. Landau D, Rosenberg N, Zivelin A, Starretz-Hacham O, Kapelushnik Y. (2009). Familial factor VII deficiency with fetal and neonatal fatal cerebral hemorrhage associated with homozygosity to Gly180Arg mutation. *Hemophilia.* 15: 774–778.
 14. Monroe, D.M.; Key, N.S. (2007). The tissue factor-factor VIIa complex: Procoagulant activity, regulation, and multitasking. *J. Thromb. Haemost.* 5, 1097–1105.
 15. McVey JH, Boswell E, Mumford AD, Kemball-Cook G, Tuddenham EG. (2000). Factor VII deficiency and the FVII mutation database. *Hum Mutat.* 17(1):3-17.
 16. Castoldi E, Govers-Riemslog JW, Pinotti M, et al. (2003). Coinheritance of factor V (FV) Leiden enhances thrombin formation and is associated with a mild bleeding phenotype in patients homozygous for the FVII 9726p5G>A (FVII Lazio) mutation. *Blood*;102: 4014–4020.



This work is licensed under Creative Commons Attribution 4.0 License

To Submit Your Article, Click Here:

[Submit Manuscript](#)

DOI:10.31579/2768-0487/121

Ready to submit your research? Choose Auctores and benefit from:

- fast, convenient online submission
- rigorous peer review by experienced research in your field
- rapid publication on acceptance
- authors retain copyrights
- unique DOI for all articles
- immediate, unrestricted online access

At Auctores, research is always in progress.

Learn more <https://auctoresonline.org/journals/journal-of-clinical-and-laboratory-research>