

# Cutaneous Mastocytosis in an 8-year-old child: Case Report and Review of the Literature

Tsveta Kalinova<sup>1</sup>, Yoanna Velevska - Vatova<sup>1</sup>, Valentina Broshtilova<sup>2</sup>, Sonya Marina<sup>3</sup>

<sup>1</sup>Department of Infectious Diseases, Parasitology and Dermatovenereology, Faculty of Medicine, Medical University of Varna, Bulgaria

<sup>2</sup>Department of Skin and Venereal Diseases, Military Medical Academy, Sofia, Bulgaria

<sup>3</sup>Medical Institute of the Ministry of Internal Affairs, Sofia, Bulgaria.

\*Corresponding Author: Tsveta Kalinova, Yoanna Velevska - Vatova<sup>1</sup>, Valentina Broshtilova<sup>2</sup>, Sonya Marina.

Received Date: 02 February 2022 | Accepted Date: 27 June 2022 | Published Date: 15 July 2022

Citation: Tsveta Kalinova, Yoanna Velevska - Vatova, Valentina Broshtilova, Sonya Marina. (2022) Cutaneous Mastocytosis in an 8-year-old child: Case Report and Review of the Literature. *J. Dermatology and Dermatitis*. 7(3); DOI:10.31579/2578-8949/092

Copyright: © 2022, Tsveta Kalinova, this is an open access article distributed under the Creative Commons Attribution License, which permits unrestricted use, distribution, and reproduction in any medium, provided the original work is properly cited.

## Abstract

Mastocytosis is a clinical condition occurring from birth to adulthood and may involve mainly the skin and/ or many organs such as the liver, bone marrow, spleen and lymph nodes. The condition has a bimodal distribution presenting in children from birth to 2 years of age and in patients older than 15. In adult patients may or may not have cutaneous involvement. In cutaneous mastocytosis the mast cells infiltrate mostly the skin but may be associated with systemic symptoms due to mast cell mediators release. In children, the disease manifests with one or more tan to red-brown papules or plaques (urticaria pigmentosa). Patients with mastocytosis may be asymptomatic or have symptoms due to mast cells degranulation – itch, flush, headache, syncope, gastrointestinal complaints of abdominal pain and diarrhea. A pathognomic sign for the disease is Darier's sign where stroking of the skin lesions provokes pronounced urtication due to mast cells degranulation. Diagnosis of cutaneous mastocytosis is based on clinical morphology of skin lesions, positive Darier's sign and histological skin lesions stained for tryptase and/or CD117. Therapeutic management involves avoiding triggers, H1-/H2- receptor blockers and symptomatic medications. All patients with cutaneous mastocytosis require follow-up examinations.

Herein, a clinical case of an 8-year-old male patient with cutaneous mastocytosis is presented. An update comprehensive review of literature focusing on clinical findings, diagnosis and modern therapeutic modalities is highlighted.

**Keywords:** mastocytosis, urticaria pigmentosa

## Introduction

Mastocytosis is a heterogeneous group of clinical entities that occur due to abnormal mast cells accumulation in the skin and other organs (liver, spleen, bone marrow, bones and gastrointestinal tract). Some authors described it as a neoplastic disease involving mast cells and their progenitors CD34+ [1].

Mastocytosis is a relatively rare disease with annual incidence 1:1 000-8000 [2, 3] which has a bimodal age distribution – neonatal group (from birth to 2 years) and teenage preponderance (over 15) [4].

It is thought that alteration in KIT-structure and activity plays a key role in the pathogenesis of mastocytosis. The most common genetic abnormality in patients with sporadic mastocytosis is a somatic mutation involving codon 816 of the c-KIT gene that leads to a substitution of the amino acid aspartic acid with valine or another amino acid and activate ligand-independent receptors [5, 6].

Many children and adults have few, if any, symptoms. In symptomatic patients the spectrum of complaints is versatile. They range from itch, flushing, dizziness, palpitation and syncope to abdominal pain and diarrhea. Nonspecific but important symptoms are fever, general malaise, weight loss, night sweats, bone pain, epigastric distress and cognitive alteration signalling extracutaneous involvement of the disease. Although extremely rare, exitus letalis has been exceptionally described due to extensive mast cell mediator release [5].

Symptoms of mastocytosis are exacerbated by physical activity, heat or hot shower, and local traumatism to skin lesions. It is established that alcohol and some drugs are implicated in precipitating the symptoms (narcotics, salicylates, NSAIDs, polymyxin B and anticholinergic drugs) [5].

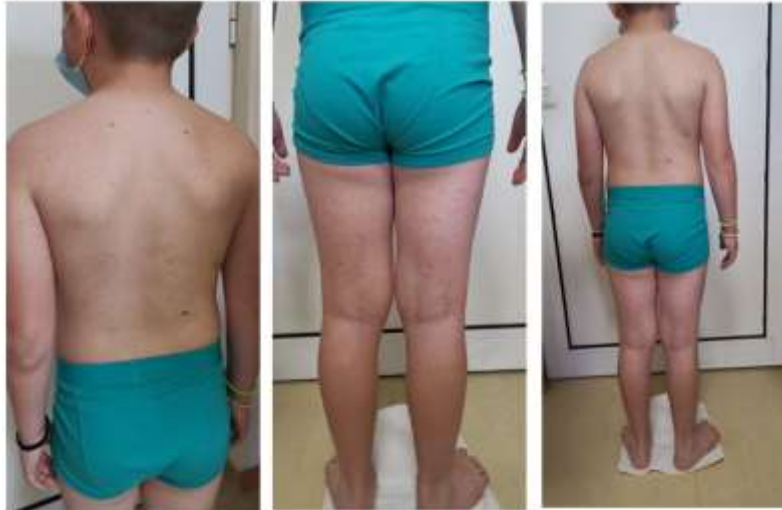Management of mastocytosis is based on avoidance of triggers and treatment with H1- and H2 – antihistamines [3]. All children with mastocytosis require regular follow-ups.

### Case report

An 8-year-old male patient referred to the outpatient department of Dermatology and Venereology with a chief complaint of itchy disseminated bumps and spots on the trunk and limbs for the past 6 months. The rash aggravated on bathing and physical activity. The patient

and the parents denied any systemic complaints as well as edema of the eyelids, lips or tongue. His past medical and family history was not significant. There was no concomitant drug intake or nutritional supplementation. No drug allergy or atopic episodes were previously registered.

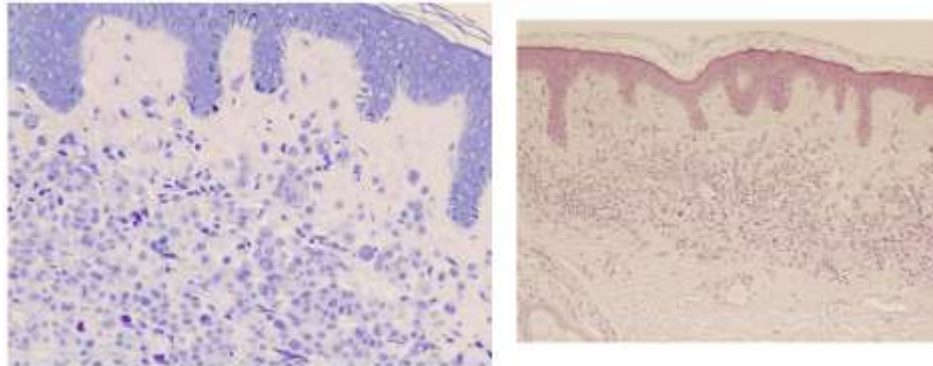
On physical examination symmetrical, yellow-tan to red-brownish macules and disseminated on the trunk and distal extremities were observed. There was no mucosal or soft tissue involvement (fig. 1 - A, B, C).



**Figure: 1** (A, B and C) Skin lesions are presented with symmetrical, disseminated yellow-tan to red-brownish macules and papules were established on back and upper limbs (A), lower limbs (B) and trunk (C).

An informed consent was obtained from patient's parents for further investigations. The complete blood tests showed normal values. The serum tryptase was not elevated. A punch biopsy was done under local anesthesia. The histopathological examination revealed orthokeratosis

with horizontal alternating parakeratosis, uneven acanthosis, hypermelanosis in lower epidermal segment, moderate interstitial and perivascular round cell infiltrate in upper dermis with large kidney-like cells, stained with toluidine blue (fig. 2 – A, B, C).



**Figure: 2** (A, B and C) Histopathological sections (HE, x 40, A) shows orthokeratosis with horizontal alternating parakeratosis, uneven acanthosis, hypermelanosis in lower epidermal segment, moderate interstitial and perivascular round cell infiltrate in upper dermis with large kidney-like cells, stained with toluidine blue (x 100, B).

### Abbreviations Used

**CD 34+** - cluster of differentiation 34+

**CM** – cutaneous mastocytosis

**CysLT** – cysteinyl leucotriene

**DCM** – diffuse cutaneous mastocytosis

**H1-/ H2** – histamine 1/2

**IL-5,6** – interleukin 5, 6

**MPCM** – maculopapular cutaneous mastocytosis

**NB-UVB** – narrow-band – Ultraviolet B

**NSAIDs** - Non-steroidal anti-inflammatory drugs

**PAF** – platelet activating factor

**PGD2** – prostaglandin D2

**PUVA** – psoralen Ultraviolet A

**SCF** – stem cell factor

**SM** – systemic mastocytosis

**TGF- $\beta$**  – transforming growth factor-  $\beta$

**TPA** – tissue plasminogen activator

## Discussion

Cutaneous mastocytosis was described for the first time by E. Nettleship and W. Tay in 1869 [7]. In 1878 A. Sangster suggested the name “urticaria pigmentosa” The first pediatric case of mastocytosis was reported by Living in 1881. In 1936, French authors revealed a systemic involvement in mastocytosis [7, 8].

According to the most recent concepts dated 2016, the spectrum of mastocytosis includes three main categories: cutaneous mastocytosis (CM), systemic mastocytosis (SM), and mast cell sarcoma (MCS) [9, 10, 11]. The most common type of mastocytosis in children is cutaneous mastocytosis. In 55% of cases, it affects children from birth to 2 years of age, in 10% in children younger than 15 years old and in 35% - over 15 years of age [6, 12]. However, in some patients, mastocytosis can persist into adulthood and may occur with systemic involvement. In children with mastocytosis mast cell mediator-related symptoms are possible. In patients with extensive skin lesions and blistering severe hypersensitivity reactions are described [3].

Pediatric mastocytosis occurs as a result of clonal proliferation due to somatic gain-of-function mutations in the gene KIT. Consequently, stem cell factor-independent activation and phosphorylation of KIT occur resulting in mast cells differentiation, enhanced survival and their subsequent accumulation in various organs [9, 10, 11, 13]. Generally, mastocytosis is not an inherited disease [3, 14]. Mast cell mediators responsible for the clinical manifestations are histamine, cysLT, PGD<sub>2</sub>, PAF, TGF- $\beta$ , IL-5, 6, chemokines heparin, TPA,  $\beta$ -tryptase, carboxypeptidase, chymase, and many lysosomal enzymes [1, 23].

The general classification of CM shows three main types of cutaneous mastocytosis: maculopapular CM (MPCM), diffuse cutaneous mastocytosis (DCM) and mastocytoma of the skin (15, 16). Maculopapular cutaneous mastocytosis (MPCM) is the most common type in any age [17]. In children it occurs within the first 6 months of life. Children may present with monomorphic or polymorphic variant of the disease [18, 19]. Monomorphic variant of MPCM presents with small, round, mostly flat, brown or red maculopapular lesions, which typically show a central, symmetrical distribution on the body and classically spare the central face, palms, and soles [20]. Polymorphic variant of MPCM presents with large, brown to dusky red skin lesions with variable size and asymmetrical distribution. A very typical feature of polymorphic variant is the involvement of the head, lateral parts of the forehead, neck and extremities [20]. Patients with polymorphic variant are more prone to spontaneous regression while in monomorphic variant, mastocytosis may persist into adulthood.

The second type of CM is the solitary mastocytoma. This type occurs most often in infants. It is manifested with a single tan- to brown, dusky red or yellow macule or nodule on the trunk, sharply demarcated from the surrounding area, with size 1-10 cm in diameter [20, 21]. Similar to other types of CM, mastocytoma also shows Darier’s sign after rubbing and blistering due to mechanical irritation [3]. Mastocytomas are benign lesions with spontaneous regress before puberty. According to the latest recommendations, the term cutaneous mastocytoma may be used in the presence of up to three lesions. When four or more lesions of this nature are found, MPCM is diagnosed [20].

The third type of CM is DCM. It is rare and severe form of CM, associated with mast cells infiltration of the entire skin. It is 5% to 13% of all childhood CM forms. DCM presents with erythroderma and generalized pachydermia (thickened skin) [18]. Less frequently, DCM manifests with generalized erythema with pseudoxanthomatous or large, tumor-like lesions [3]. Clinical symptoms in CM are result from mast cell-mediators release. The main symptoms are itch, erythema and edema of the lesions, flushing, blistering and dermographism. Once dermal mast cells are activated, skin lesions become erythematous, edematous and pruritic, sometimes also followed by the emergence of vesicles as well as serous or hemorrhagic blisters, particularly within the first 12–24 months from disease onset [3]. Flushing is caused by increased blood flow through the skin as a result of vasoactive substances release. The presence of flushing is not just a cutaneous sign but also a marker for a systemic vascular response to mast cells mediators and can lead to hypotension and syncope [22]. Thus, flushing in a child with CM should be a warning sign indicating close watchfulness of the patient [3].

According to National Institutes of Health, 83% of children present with pruritus, 65% - flushing, 53% - vesicles, 41% - abdominal pain, 18% - bone pain and headache in 12%. High level of histamine may increase gastric-acid secretion resulting in bleeding and peptic ulcers [12].

### Potential triggers of mast cell degranulation are (2, 3):

- Physical – physical activity, pressure, rubbing, friction, cold, heat;
- Nutritional – histamine-rich foods, caffeine, hot spices, alcohol, histamine-liberators (alcohol, eggs, chocolate, strawberries, pineapples, exotic fruits, sea food);
- Infectious – some viral infections;
- Teething
- Emotional stress
- Allergens – Hymenoptera allergens and venoms, pollens, dust mite, animal dander, molds, food;
- Drugs – NSAIDs, opioids, muscle relaxants, cough medications, contrast media, Quinolones;
- Vaccinations

## Diagnosis

According to the EU/US consensus group, the patient is diagnosed with cutaneous mastocytosis when [15, 25]:

1. No signs or criteria of SM
2. There are typical skin lesions of mastocytosis
3. There is positive Darier’s sign
4. One or two of the following minor criteria are presented:
  - increased number of mast cells in biopsy section and activating KIT-mutation in lesional skin.

A major CM criterion is the presence of Darier’s sign – reddening and swelling of the lesion after physical irritation [15].

A patient is diagnosed with mastocytosis based on skin lesions morphology, positive Darier’s sign and histology assessment of skin lesions for tryptase and/or CD117 [21, 24]. Presence of the KIT D816V-mutation in lesional skin confirms the diagnosis of CM [3].

## Treatment

The effective treatment involves avoidance of triggering factors and/ or treatment of mast cell mediators – related symptoms.

For every acute, life-threatening reaction in CM an “Epi-Pen” is highly recommended. Its usage is based on symptoms, course and subtype of CM. Current recommendations suggest to provide it to children suspected for CM presenting with extensive skin lesions, a history of severe systemic symptoms or anaphylaxis and highly elevated tryptase levels [3].

CM is managed mostly by symptomatic treatment. In most children with CM no intensive treatment is required. The main purpose in these patients is to put under control the main symptoms. Major treatment options are subdivided into first-line drugs and alternative drugs.

In patients with itch, flushing and blistering, first-line drugs are antihistamines (H1-antagonists). As an alternative H2-antihistamines, short course of corticosteroids, topical corticosteroids, leucotrien antagonists, Pimecrolimus cream, Topical sodium cromolyn are recommended. In addition, excision of mastocytomas and NB-UVB/PUVA are described [3, 25]. Gastrointestinal manifestations of mastocytosis (abdominal pain, diarrhea, reflux, ulceration) are managed with H2-antihistamines. As an alternative - proton pump inhibitors, oral sodium cromolyn and oral corticosteroids are used [3]. In case of neuro-psychiatric symptoms (cognitive impairment, headache, loss of concentration) it is recommended to use H1- and H2-antihistamines. In addition, a specific treatment for the individual patients is required [3].

## Conclusion

Pediatric mastocytosis is a benign condition with a favourable prognosis. CM has the tendency to regress spontaneously around puberty. Children with CM present with few symptoms and they have fewer triggers of mast cell mediators compared with adult patients. The risk of unforeseeable reactions due to presence of triggering factors is unpredictable, so a high index of suspicion should be kept in all pediatric medical caregivers. Although the diagnosis of mastocytosis is not difficult, many patients are wrongly diagnosed because of the variable clinical manifestation of the disease. That is why, in children with itchy polymorphic rash cutaneous mastocytosis should be considered.

## References

1. Silva I, Carvalho S, Pinto P, Machado S, Rosado J. (2008). Mastocytosis: a rare case of anaphylaxis in paediatric age and literature review. *Allergologia et Immunopathologia*. 36(3):154-163.
2. Barete S. (2014). Les mastocytoses. *Annales de dermatologie et de vénéréologie*. (141): 698-714.
3. Lange M, Hartmann K, Carter M, Siebenhaar F, Alvarez-Twose I et al. (2021). Molecular Background, Clinical Features and Management of Pediatric Mastocytosis: *Int. J. Mol. Sci.* 22:2586.
4. Frieri M, Quershi M. (2013). Pediatric Mastocytosis: A Review of the Literature. *Pediatr Allergy Immunol Pulmonol*. 26(4):175-180.
5. Bologna J, Jorizzo J, Schaffer J. (2012). *Dermatology. Neoplasms of the skin. Mastocytosis*. 3-rd edition. Elsevier. 1994-1998.
6. Guleva D, Mateev G. (2017). Mastocytosis in childhood. *Practical Pediatrics*.
7. Sagher F, Even-Paz Z. (1967). Mastocytosis and the Mast Cell. *Basel, Karger*. 4-7.
8. Yungareva I, Dimitrova J, Ivanova B, Popchristova E, Koleva N, Yordanov T, Kalinova Ts, Tchupetlovska M, Temelkova I, Marina S. (2020). Urticaria pigmentosa. A clinical case and review of the literature. *Med Info*.
9. Valent P, Akin C, Metcalfe D. (2017). Mastocytosis: 2016 updated WHO classification and novel emerging treatment concepts. *Blood*. (129):1420-1427.
10. Valent P, Horny H, Escribano L, Longley B, Li C, Schwartz L, et al. (2001). Diagnostic criteria and classification of mastocytosis: A consensus proposal. *Leuk. Res*. 25:603-625.
11. Valent P, Akin C, Gleixner K, Sperr W, Reiter A, et al. (2019). Multidisciplinary challenges in mastocytosis and how to address with personalized medicine approaches. *Int. J. Mol. Sci.* 20:1-17.
12. Kettelhut B, Metcalfe D. Mastocytosis. (1991). *J Invest Dermatol*. 96: 115-118.
13. Komi DEA, Rambasek T, Wöhrl S. (2018). Mastocytosis: From a Molecular Point of View. *Clin. Rev. Allergy Immunol*. 54:397-411.
14. Wasag B, Niedoszytko M, Piskorz A, Lange M, Renke, J, Jassem E, et al. (2011). Novel, activating KIT-N822I mutation in familial cutaneous mastocytosis. *Exp. Hematol*. 39:859-865.
15. Hartmann K, Escribano L, Grattan C, Brockow K, Carter M, et al. (2016). Cutaneous manifestations in patients with mastocytosis: Consensus report of the European Competence Network on Mastocytosis; the American Academy of Allergy, Asthma & Immunology; and the European Academy of Allergology and Clinical Immunology. *J. Allergy Clin. Immunol*. 137:35-45.
16. Hartmann K, Valent P, Horny H. (2018). Cutaneous mastocytosis. In *World Health Organization (WHO) Classification of Skin Tumours*, 4th ed. Elder D, Massi D, Scolyer R, Willemze R, International Agency for Research on Cancer: Lyon, France. 275-278.
17. Castells M, Metcalfe D, Escribano L. (2011). Diagnosis and treatment of cutaneous mastocytosis in children: Practical recommendations. *Am. J. Clin. Dermatol*. 12:259-270.
18. Matito A, Azaña J, Torrelo A, Alvarez-Twose I. (2018). Cutaneous Mastocytosis in Adults and Children: New Classification and Prognostic Factors. *Immunol. Allergy Clin. N. Am*. 38:351-363.
19. Brockow K, Akin C, Huber M, Metcalfe D. (2003). Assessment of the extent of cutaneous involvement in children and adults with mastocytosis: Relationship to symptomatology, tryptase levels, and bone marrow pathology. *J. Am. Acad. Dermatol*. 48:508-516.
20. Hartmann K, Escribano L, Grattan C, Brockow K, Carter M, et al. (2016). Cutaneous manifestations in patients with mastocytosis: Consensus report of the European Competence Network on Mastocytosis; the American Academy of Allergy, Asthma & Immunology; and the European Academy of Allergology and Clinical Immunology. *J. Allergy Clin. Immunol*. 137:35-45.
21. Leung AKC, Lam J, Leong K. (2019). Childhood Solitary Cutaneous Mastocytoma: Clinical Manifestations, Diagnosis, Evaluation, and Management. *Curr. Pediatr. Rev*. 15:42-46.
22. Alvarez-Twose I, Vañó-Galván S, Sánchez-Muñoz L, Morgado J, Matito A, et al. (2012). Increased serum baseline tryptase levels and extensive skin involvement are predictors for the severity of mast cell activation episodes in children with mastocytosis. *Allergy*. 67:813-818.
23. Valent P, Akin C, Hartmann, K, Nilsson G, Reiter A, et al. (2020). Mast cells as a unique hematopoietic lineage and cell system: From Paul Ehrlich's visions to precision medicine concepts. *Theranostics*. 10:10743-10768.
24. Lange M, Ługowska-Umer H, Niedoszytko M, Wasag B, Limon J, et al. (2016). Diagnosis of Mastocytosis in Children and Adults in Daily Clinical Practice. *Acta Dermato-Venereol*. 96:292-297.
25. Husain Z, Waterman D, Ellison K, DeSimone JA. (2017). Management of poorly controlled indolent systemic mastocytosis using narrowband UVB phototherapy. *Cutis*. 99:30-33.