

Primary Anti-Phospholipid Antibody Syndrome presenting as Multiple Cerebral Venous Sinus Thrombosis: An Arduous Manifestation.

Richmond R Gomes

Medicine, Ad-Din Women's Medical College Hospital, Dhaka Bangladesh.

Corresponding Author: Richmond R Gomes, Medicine, Ad-Din Women's Medical College Hospital, Dhaka Bangladesh.

Received Date: February 26, 2022 | **Accepted Date:** June 10, 2022 | **Published Date:** June 21, 2022

Citation: Richmond R Gomes. (2022). Primary Anti-Phospholipid Antibody Syndrome presenting as Multiple Cerebral Venous Sinus Thrombosis: An Arduous Manifestation. *J. Brain and Neurological Disorders*. 5(2); DOI:10.31579/2642-9730/019

Copyright: © 2022, Richmond R Gomes, this is an open access article distributed under the Creative Commons Attribution License, which permits unrestricted use, distribution, and reproduction in any medium, provided the original work is properly cited.

Abstract:

Lupus anticoagulants (LA) are circulating autoantibodies, primarily directed against phospholipids, that prolong the partial thromboplastin time. Antiphospholipid antibody syndrome (APS) is an autoimmune disorder, mainly found in young females, presenting with vascular thrombosis and/obstetric complications. Thrombosis at anatomically significant sites may lead to considerable morbidity and/or mortality. We here present a 22 years old lady with no prior rheumatological history, presented with sudden onset headache, vomiting, diplopia who later diagnosed with multiple cerebral venous sinus thrombosis (CVST) due to with primary APS. MR venography was instrumental in diagnosis. Except for mild headache, the other symptoms responded to anticoagulant. Such massive cerebral venous thrombosis is extremely rare in primary APS.

Key Words: lupus anticoagulants; antiphospholipid antibody syndrome; diplopia; mr venography; anticoagulant

Introduction

Antiphospholipid syndrome is characterized by clinical features which include arteriovenous thrombosis, recurrent pregnancy loss, thrombocytopenia, and the presence of antiphospholipid antibodies including anticardiolipin antibody (aCL) and lupus anticoagulant (LA). [1,2]. Antiphospholipid syndrome was first observed in a patient with systemic lupus erythematosus,² but has also been observed in patients with other connective tissue disorders, as well as with infections or drug-induced disorders¹-secondary APS. Antiphospholipid syndrome in the absence of such underlying conditions has been observed, and is defined as primary APS [3,4].

The most common clinical manifestation of APS is venous thrombosis, especially deep vein thrombosis of the lower extremities and pulmonary embolism, followed by thrombosis of the thoracic, abdominal or pelvic veins [5,6]. In approximately one fourth of patient's arterial thrombosis may be the initial manifestation. Although cerebral venous thrombosis (CVT) is rare as initial presentation of APS⁷, this diagnosis should be considered in a patient with an unusual headache and no known risk factors for thrombosis.

Case report:

A 22-year-old pleasant Bangladeshi lady, not known to have hypertension, diabetes mellitus or bronchial asthma presented to us with

the complaints of double vision, photophobia and worsening left occipital headache radiated to the temporal area for the previous 7 days. The pain was worse on awakening, and waxed and waned. Coughing, sneezing or straining at defecation increased the headache. She also had several episodes of generalized tonic clonic seizures over preceding ten days. She reported several months' history of recurrent morning dull headache with vomiting. She denied any limb weakness, altered sensorium, fever, visual, and speech or memory disturbances. She also reported short-term use of medications for suspected vascular headache with amitriptyline and propranolol without any improvement but there was no history of oral contraceptive use. She also denied history of trauma to the head, any surgical intervention or any previous thrombosis. There was no joint pain, oral ulcer or skin rash. She had two child and no history of menstrual irregularities, previous abortion or bad obstetric history. Her family history was also non-conclusive of any thrombotic disorder. A physical examination revealed bilateral grade II/IV papilledema eye fundus, with no other neurological focal signs except right sided sixth cranial nerve palsy (Figure 1). The patient was awake and alert, in no acute distress, with normal vital signs. There was no evidence of lower limb deep venous thrombosis. Other physical exams were unremarkable.

Initial laboratory investigations revealed normal blood counts except thrombocytopenia (104000/ μ L), TSH as well as kidney and liver function. Electrocardiography revealed sinus tachycardia. Brain Magnetic Resonance Imaging (MRI) revealed cord sign (Figure 2- black arrow),

dense vein sign (figure -3, black arrow) and empty delta sign (figure 3 – yellow arrow). Magnetic Resonance Venogram (MRV) suggestive of

thrombus in superior sagittal sinus, straight sinus, left transverse sinus and part of left sigmoid sinus (Figure 4).

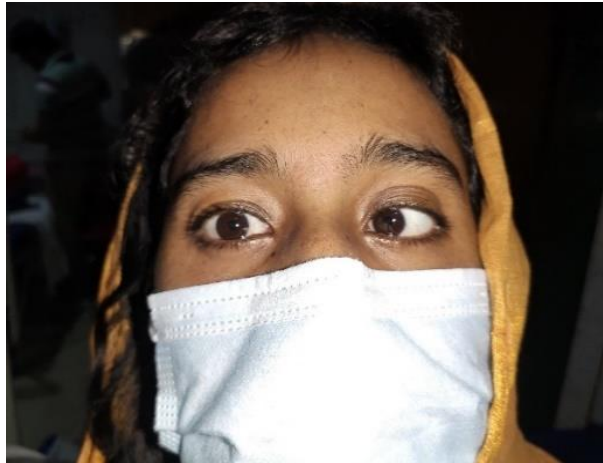

Figure 1: showing right sixth cranial nerve palsy and

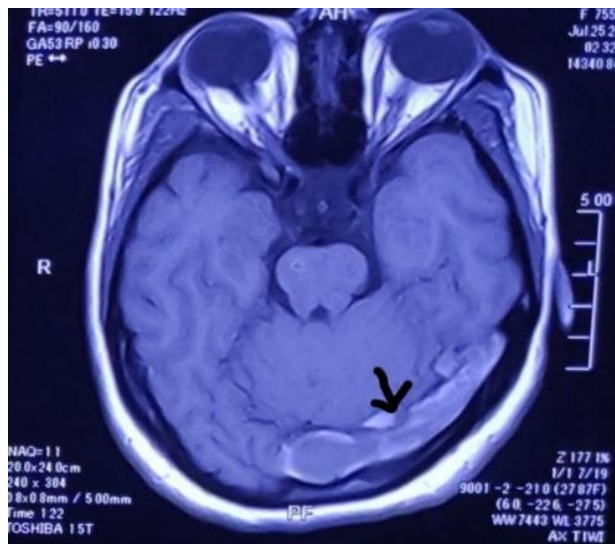

Figure 2: MRI of brain showing cord sign.(black arrow)

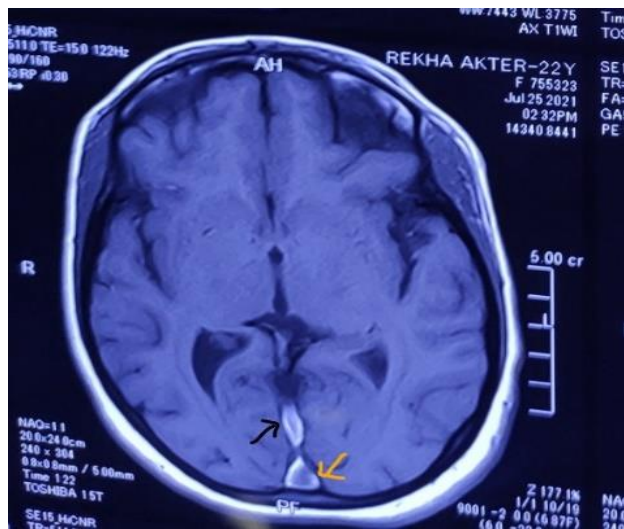


Figure 3: MRI of brain showing dense vein sign(black arrow) and empty delta sign(yellow arrow)

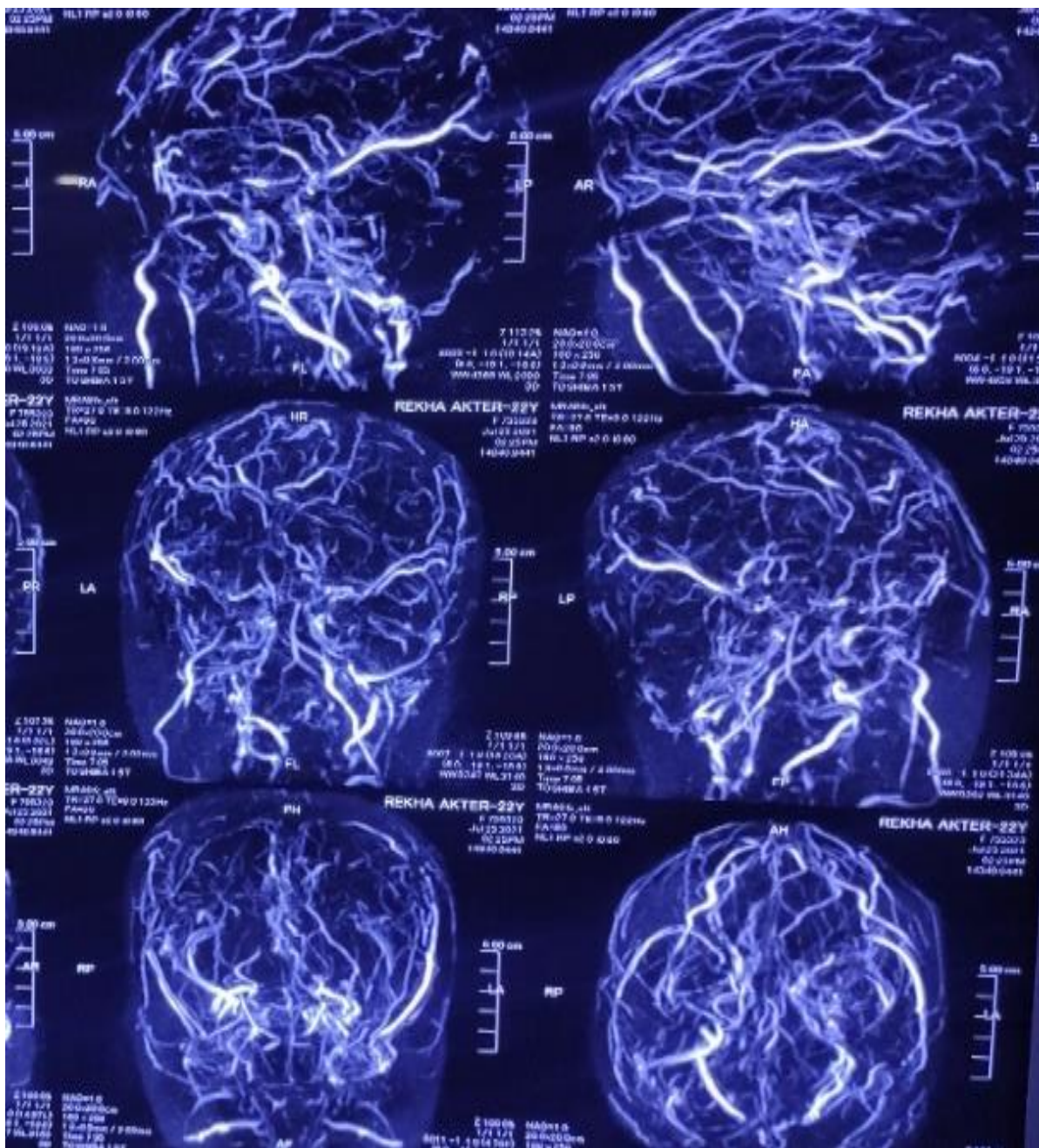


Figure 4: MRV showing thrombosis in superior sagittal sinus, straight sinus, left transverse sinus and part of left sigmoid sinus

Tests for other autoimmunity markers (antinuclear antibody, ENA profile-ANCA, c-ANCA) were negative. Laboratory tests performed for the assessment of a hypercoagulable state revealed the following results: d-dimer 6.74 mg/mL (normal <0.55 µg/mL), fibrinogen 754.5 mg/dL (normal 200-400 mg/dL). apt was raised (patient 56 secs, control 35 secs). Lupus anticoagulant (by LAC screen with DRVVT confirmation) was positive. Antibodies against cardiolipin and beta 2 glycoprotein were negative. No changes were found in any other proteins tested (antithrombin III, Factor V Leiden, von Willebrand factor, homocysteine) except slightly reduced protein S level (40% - normal 60-105%). Factor VIII level was not done due to unavailability.

So, considering our provisional of multiple cerebral venous sinus thrombosis secondary to primary anti phospholipid antibody syndrome was made and treatment with low molecular weight heparin along with

oral apixaban was started along with anti-convulsant levetiracetam and resulted in immediate symptomatic improvement. Patient's hospital stay was uncomplicated, and she was discharged on day 8 on oral anticoagulation with apixaban.

On follow up, after three months, the lupus anticoagulant was still positive. Thus, the antiphospholipid antibody was persistent, supporting our initial provisional diagnosis. The patient remains clinically well on oral anticoagulation with apixaban, without any further episode of thrombosis. The plan of treatment is continuing anticoagulation for 6 months.

Discussion

Antiphospholipid antibodies are predominantly acquired serum immunoglobulins with affinity for anionic and neutral phospholipid-

containing moieties, such as cellular membranes of vascular endothelium. The two most extensively studied a PL are a CL and the LA [3,8]. In the past decade a syndrome—the antiphospholipid syndrome—has been described in which systemic and cerebral venous and arterial occlusions are seen at a relatively young age and with a relatively high risk of recurrent thrombo-occlusive events [9,10,11,12].

Antibodies to phospholipids, first described in association with systemic lupus, are present at low titer in approximately 4% of the general population [13]. Persistent high titers, in particular of IgG anticardiolipin, are clearly associated with thrombosis at multiple sites. In the absence of connective tissue disease, the antiphospholipid syndrome has been associated with a number of neurological presentations including chorea, seizure disorder, psychiatric disturbance, and transverse myelitis [2,11]. The case presented here illustrates the association of antiphospholipid antibodies with cerebral venous sinus thrombosis.

CVST is a rare disorder carrying a relatively high mortality (10% to 15%) [14,15]. With the advent of MRI and MR angiography and digital subtraction angiography, the prevalence and natural history of CVST are being refined [16,17,18]. Risk factors for CVST include systemic noninfectious conditions such as pregnancy and puerperium, hyper viscosity syndromes, Behcet's disease, coagulopathies including activated protein C resistance and factor V Leiden mutation [19,20,21]. and collagen vascular diseases [22,23,24]. The presence of a PL (a CL or LA) has been suggested as a risk factor for CVST [6,11,25,26]. but the clinical, radiological, and outcome profiles have not been determined or systematically studied, mainly because of the scarcity of the reported cases.

The pathogenesis of thrombosis associated with antiphospholipid syndrome is not clearly understood. Recently, antibodies against the β_2 -GPI-phospholipid complex [27,28], prothrombin-phospholipid complex [4], protein S-phospholipid complex [28], and activated protein C-phospholipid complex [28], have been detected in the serum of patients with antiphospholipid syndrome. β_2 -GPI is a cofactor which is necessary for the binding of a CL to cardiolipin. Thea CL reacts with the β_2 -GPI-cardiolipin complex which inhibits the prothrombinase activity of platelets and the generation of factor X a on the surface of activated platelets in patients with antiphospholipid syndrome [27,29,30,31]. In addition, a slightly decreased protein S antigen level and moderately decreased protein S activity level was detected in the present case. These findings might be related to the presence of antibody against the protein S phospholipid complex. Protein S has an anticoagulant function by directly binding to factor V a, and this function is independent of activated protein C [32].

Molecular mimicry has been demonstrated in experimental models between B2GPI related peptides and bacterial, viral and tetanus toxoids suggesting that in predisposed individuals contact with microorganisms or their products could activate potentially autoreactive lymphocytes [33,34].

The etiologies of sinus and cerebral venous thrombosis can be divided into infectious and non-infectious types. Various non-infectious etiologies, such as pregnancy, post-partum, oral contraceptives, head injury, tumors, Behcet's disease, nephritic syndrome, have been reported [35]. However, 10 of 38 cases of sinus and cerebral venous thrombosis had no definite etiology [35]. The presence of a CL or LA was not examined in these cases. Recently, tests for a CL and LA were made in a series of 40 patients with cerebral venous thrombosis, finding a CL or LA in four patients [36]. An increased a CL level was founding three of another series of 40 patients with cerebral venous thrombosis [20]. These reports suggest that some patients with a diagnosis of sinus and cerebral venous thrombosis of unknown etiology may have primary antiphospholipid syndrome. Therefore, primary antiphospholipid syndrome should be

considered in the evaluation of patients with sinus and cerebral venous thrombosis of unknown etiology.

The majority of cerebrovascular disorders associated with antiphospholipid syndrome by thrombosis or thromboembolism [8,11]. Sinus and cerebral venous thrombosis relatively rare. The nine reported cases [11,25,37,38]. showed no specific features in terms of the CT findings and neurological symptoms, like sinus and cerebral venous thrombosis of other etiologies. However, serological studies showed a positive LA test result and/or increased acyl level in all cases. These nine patients, four males and five females, were aged from 21 to 52 years (average 35.6 years). Four of the five females had experienced one or more spontaneous abortions, and sinus and cerebral venous thrombosis occurred during pregnancy or just after delivery in three. Four patients developed their arterial and/or venous thrombosis, and five had thrombocytopenia. Three cases were associated with systemic lupus erythematosus. All nine patients were treated with anticoagulants (heparin and/or warfarin) and/or platelet-activating agent (aspirin), and seven patients with steroids. Craniotomy was performed in two of the three patients under a diagnosis of hemorrhagic infarction. One patient with superior sagittal sinus and transverse sinus thrombosis received a local injection of urokinase. These procedures all yielded good results.

Features of cerebral venous sinus thrombosis include symptoms of raised intracranial pressure and papilla edema in chronic cases and impaired consciousness, seizures and focal symptoms/signs in acute cases. MRI with MR venography of brain is the investigation of choice to diagnose CVST. Treatment options for CVST include treatment of underlying condition heparin/warfarin in acute presentations, acetazolamide/steroids for raised intracerebral pressure, anticonvulsants for seizures, antiplatelet agents multiple cerebral venous sinus thrombosis is very rare. In a recent study from India, out of a series of CVT cases, only 20% were multiple [39]. The mortality in this group of patients was extremely high. We report this case to highlight this rare complication of APS. Such a manifestation of primary APS has been reported once previously from the subcontinent [40].

Conclusion

Our report expands the cerebrovascular manifestations associated with LAs to include CVST and should be considered in the differential diagnosis of cerebral venous thrombosis. The case demonstrates the importance of screening for antiphospholipid antibodies in patients presenting with cerebral venous sinus thrombosis. In patients where such antibodies are identified clinicians should be aware not only of the risk of recurrent thrombosis but also of the possible later development of associated immunologically mediated conditions.

Conflict of interest: None declared

References

1. Harris EN. (1990). Antiphospholipid antibodies. *Br J Haematol.* 74:1-9.
2. Hughes GRV, Harris EN, Gharavi AE (1986). The anticardiolipin syndrome. *J Rheumatol.* 13:486-489.
3. Alarcon-Segovia Da. (1989). Sanchez-Guerrero J: Primary antiphospholipid syndrome. *J Rheumatol* 16:482-488.
4. Asherson RA, Khamashta MA, Ordi-Ros J, Derksen RHW, Machin SJ, Barquinero J, Outt HH, Harris EN, Vilardell-Torres M, Hughes GRV. (1989). The primary antiphospholipid syndrome: major clinical and serological features. *Medicine (Baltimore).* 68:366-374.
5. Martinelli I, Panzeri D, Taioli E, Mannucci PM. (1997). Risk Factors for Deep Venous Thrombosis of the Upper Extremities *Annals of Internal Medicine.* 126:707-711.

6. Provenzale JM, Ortel TL, Allen NB. (1998). Systemic thrombosis in patients with antiphospholipid antibodies: lesion distribution and imaging findings. *AJR Am J Roentgenol.* 170:285-290.
7. Sakamoto S, Akutsu K, Kawase K, Takada T, Seyama H, Takahashi J, Miyamoto S, Nonogi H, Takeshita S. (2008). Simultaneous presentations of deep vein thrombosis and cerebral sinus thrombosis in a case of primary antiphospholipid syndrome. *Angiology.* 59:765-768.
8. The Antiphospholipid Antibodies in Stroke Study Group. (1990). Clinical and laboratory findings in patients with antiphospholipid antibodies and cerebral ischemia. *Stroke.* 21:1268-1273.
9. Coull BM, Levine SR, Brey RL. (1992). The role of antiphospholipid antibodies in stroke. *Neurol Clin.* 10:125-143.
10. Feldmann E, Levine SR. (1995). Cerebrovascular disease with antiphospholipid antibodies: immune mechanisms, significance, and therapeutic options. *Ann Neurol.* 37(1):114-130.
11. Levine SR. (1994). Antiphospholipid antibodies and the nervous system: clinical features mechanisms and treatment. *Semin Neurol.* 14:168-178.
12. Love PE, Santoro SA. (1990). Antiphospholipid antibodies: anticardiolipin and the lupus anticoagulant in systemic lupus erythematosus (SLE) and in non-SLE disorders. *Ann Intern Med.* 112:682-698.
13. The APASS group. (1993). Anticardiolipin antibodies are an independent risk factor for first ischaemic stroke. *Neurology.* 43:2069-2073.
14. Bousser MG, Chiras J, Bories J, Castaigne P. (1985). Cerebral venous thrombosis: a review of 38 cases. *Stroke.* 16:199-213.
15. Preter M, Tzourio C, Ameri A, Bousser MG. (1996). Long term prognosis in cerebral venous thrombosis: follow-up of 77 patients. *Stroke.* 27:243-246.
16. Isensee Ch, Reul J, Thron A. (1994). Magnetic resonance imaging of thrombosed dural sinuses. *Stroke.* 25:29-34.
17. Tsai FY, Wang AM, Matovich VB, Lavin M, Berberian B, Simonson TM, Yuh WTC. (1995). MR staging of acute dural sinus thrombosis: correlation with venous pressure measurements and implications for treatment and prognosis. *AJNR Am J Neuroradiol.* 16:1021-1029.
18. Vogl TJ, Bergman C, Villringer A, Einhaupl K, Lissner J, Felix R. (1994). Dural sinus thrombosis: value of venous MR angiography for diagnosis and follow-up. *AJR Am J Roentgenol.* 162:1191-1198.
19. Zuber M, Toulon P, Marnet L, Mas J-L. (1996). Factor V Leiden mutation in cerebral venous thrombosis. *Stroke.* 27:1721-1723.
20. Deschiens MA, Conard J, Horellou MH, Ameri A, Preter M, Chedru F, Samana MM, Bousser M-G. (1996). Coagulation studies, factor V Leiden, and anticardiolipin antibodies in 40 cases of cerebral venous thrombosis. *Stroke.* 27:1724-1730.
21. Dulli D, Luzzio C, Williams EC, Schutta HS. (1996). Cerebral venous thrombosis and activated protein C resistance. *Stroke.* 27:1731-1733.
22. Ameri A, Bousser MG. Cerebral venous thrombosis. *Neurol Clin.* 10:87-111.
23. Bousser MG, Barnett HJM. (1992). Cerebral venous thrombosis. In: Barnett HJM, Mohr JP, Stein BM, Yatsu FM, eds. *Stroke: Pathophysiology, Diagnosis, and Management.* New York, NY: Churchill Livingstone, Inc. 517-537.
24. Lefkowitz D. (1989). Cortical thrombophlebitis and sinus venous disease. In: Vinken PJ, Bruyn GW, Klawans HL, Toole JP. *Handbook of Clinical Neurology.* New York, NY: Elsevier Science Publishers BV. 395-423.
25. Vidaihet M, Piette JC, Wechsler B, Bousser MG, Brunet P. (1990). Cerebral venous thrombosis in systemic lupus erythematosus. *Stroke.* 21:1226-1231.
26. Mokri B, Jack CR Jr, Petty GW. (1993). Pseudotumor syndrome associated with cerebral venous sinus occlusion and antiphospholipid antibodies. *Stroke.* 24:469-472.
27. McNeil HP, Simpson RJ, Chesterman CN, Krilis SA (1990). Antiphospholipid antibodies are directed against a complex antigen that includes a lipid-binding inhibitor of coagulation: β_2 -GPI apolipoprotein(H). *Proc Natl Acad Sci U S A* 87: 4120-4124.
28. Oosting JD, Derksen RHW, Entjes HT, Bouma BN, de Groot PG. (1992). Lupus anticoagulant activity is frequently dependent on the presence of β_2 -glycoprotein I. *Thromb Haemost.* 67:499-502.
29. Machin SJ. (1996). Platelets and antiphospholipid antibodies. *Lupus.* 5:386-387.
30. Nimpf J, Bevers EM, Bomans PH, Till U, Wurm H, Kostner GM, Zwaal RF: Prothrombinase activity of human platelets is inhibited by β_2 -glycoprotein I
31. Oosting JD, Derksen RHW, Entjes HT, Bouma BN, de Groot PG. (1992). Lupus anticoagulant activity is frequently dependent on the presence of β_2 -glycoprotein I. *Thromb Haemost.* 67:499-502.
32. Heeb MJ, Mesters RM, Tans G, Rosing J, Griffin JH. (1993). Binding of protein S to factor Va associated with inhibition of prothrombinase that is independent of activated protein C. *J Biol Chem.* 268:2872-2877.
33. Inic-Kanada A, Stojanovic M, Zivkovic I, Kosec D, Micic M, Petrusic V, Zivancevic-Simonovic S, Dimitrijevic L. (2009). Murine monoclonal antibody 26 raised against tetanus toxoid cross-reacts with beta2-glycoprotein I: its characteristics and role in molecular mimicry. *Am J Reprod Immunol.* 61:39-51.
34. Blank M, Asherson RA, Cervera R, Shoenfeld Y. (2004). Antiphospholipid syndrome infectious origin. *J Clin Immunol.* 24:12-23.
35. Bevers EM, Galli M, Barbui T, Comfurius P, Zwaal RFA. (1991). Lupus anticoagulant IgG's (LA) are not directed to phospholipids only, but to a complex of lipid bound human prothrombin. *Thromb Haemost* 66:629-632.
36. Daif A, Awada A, Al-Rajeh S, Abduljabbar M, Al Tahan AR, Obeid T, Malibary T. (1995). Cerebral venous thrombosis in adults. A study of 40 cases from Saudi Arabia. *Stroke.* 26:1193-1195.
37. Khoo KBK, Long FL, Tuck RR, Allen RJ, Tymms KE. (1995). Cerebral venous sinus thrombosis associated with the primary antiphospholipid syndrome. Resolution with local thrombolytic therapy. *Med J Aust.* 162:3032.
38. Yamaguchi T, Nagayama M, Shimoda M, Shibata M, Shinoda M, Sato O, Yanagimachi T, Nagayama T, Shinohara Y. (1993). [A case of antiphospholipid antibody syndrome complicated by cerebral venous thrombosis in systemic multiple thromboses]. *CI Kenkyu.* 15:95-100.
39. Patil VC, Choraria K, Desai N, Agrawal S. (2014). Clinical profile and outcome of cerebral venous sinus thrombosis at tertiary care center. *J Neurosci Rural Pract.* 5:218-24.
40. Sarkar R, Paul R, Thakur I, Sau TJ, Roy D, Pandey R, Mani A, Ruia AV. (2018). Multiple Cerebral Venous Sinus Thrombosis as First Manifestation of Primary Anti-Phospholipid Antibody Syndrome. *Journal of the associations of Physicians of India.* 66.