

## Ichthyosiform Mycosis Fungoides: An Atypical Variant Of Cutaneous T-Cell Lymphoma: About A Case and Literature Review

Elharrouni Alaoui Aicha\*, Elloudi Sara, Douhi Zakia, Baybay Hanane, Mernissi Fz

Department of dermatology ,CHU Hassan II, FES ,Morocco

\*Corresponding author: Elharrouni Alaoui Aicha, Department of dermatology, CHU Hassan II, FES, Morocco

Received date: **January 30, 2020**; Accepted date: **February 12, 2020**; published date: **February 17, 2020**

Citation: Elharrouni Alaoui Aicha, Elloudi Sara, Douhi Zakia, Baybay Hanane, Mernissi Fz (2020) Ichthyosiform Mycosis Fungoides: An Atypical Variant Of Cutaneous T-Cell Lymphoma : About A Case And Literature Review. J Clinical Research and Reports, 2(4); DOI:10.31579/2690-1919/030

Copyright: © 2020 Elharrouni Alaoui Aicha. This is an open access article distributed under the Creative Commons Attribution License, which permits unrestricted use, distribution, and reproduction in any medium, provided the original work is properly cited.

### Abstract

Acquired ichthyosis is a known paraneoplastic sign of lymphoproliferative malignancies, with histopathologic findings that are nonspecific, revealing no insinuation of the underlying neoplasm.

Mycosis fungoides (MF) is a skin malignancy of T helper lymphocytes with a wide clinical spectrum. Among the atypical variants of MF, there is an ichthyosis- like presentation. However, to date, rare cases of ichthyosiform MF has been reported. We report here the clinical and histopathological features of patient with IMF.

**Key Words:** cutaneous T-cell lymphoma; mycosis fungoides ; Ichthyosiform variant

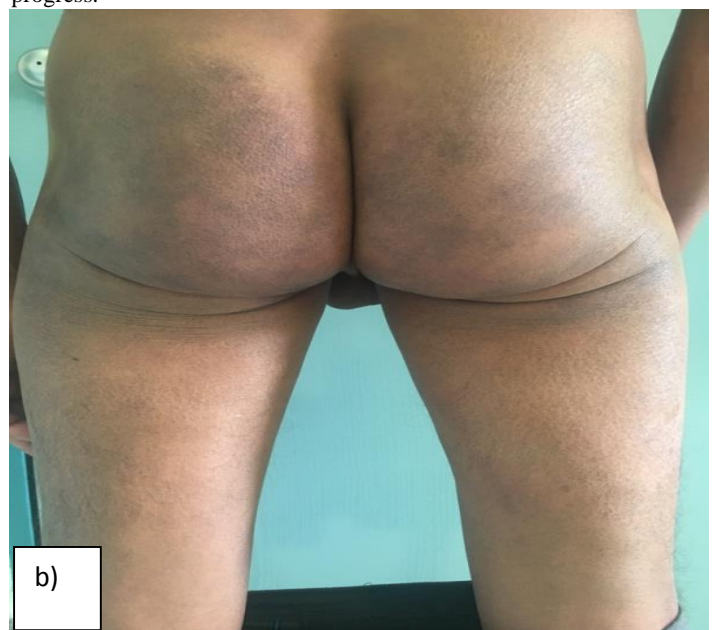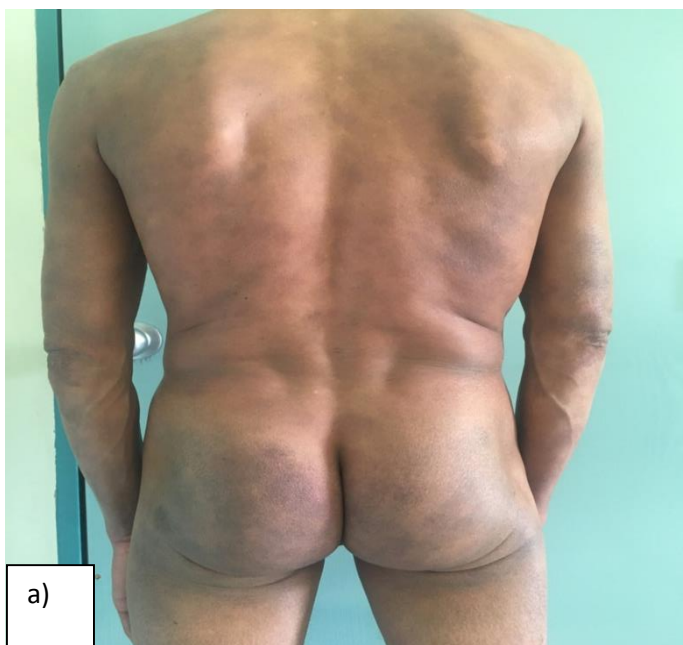### Introduction:

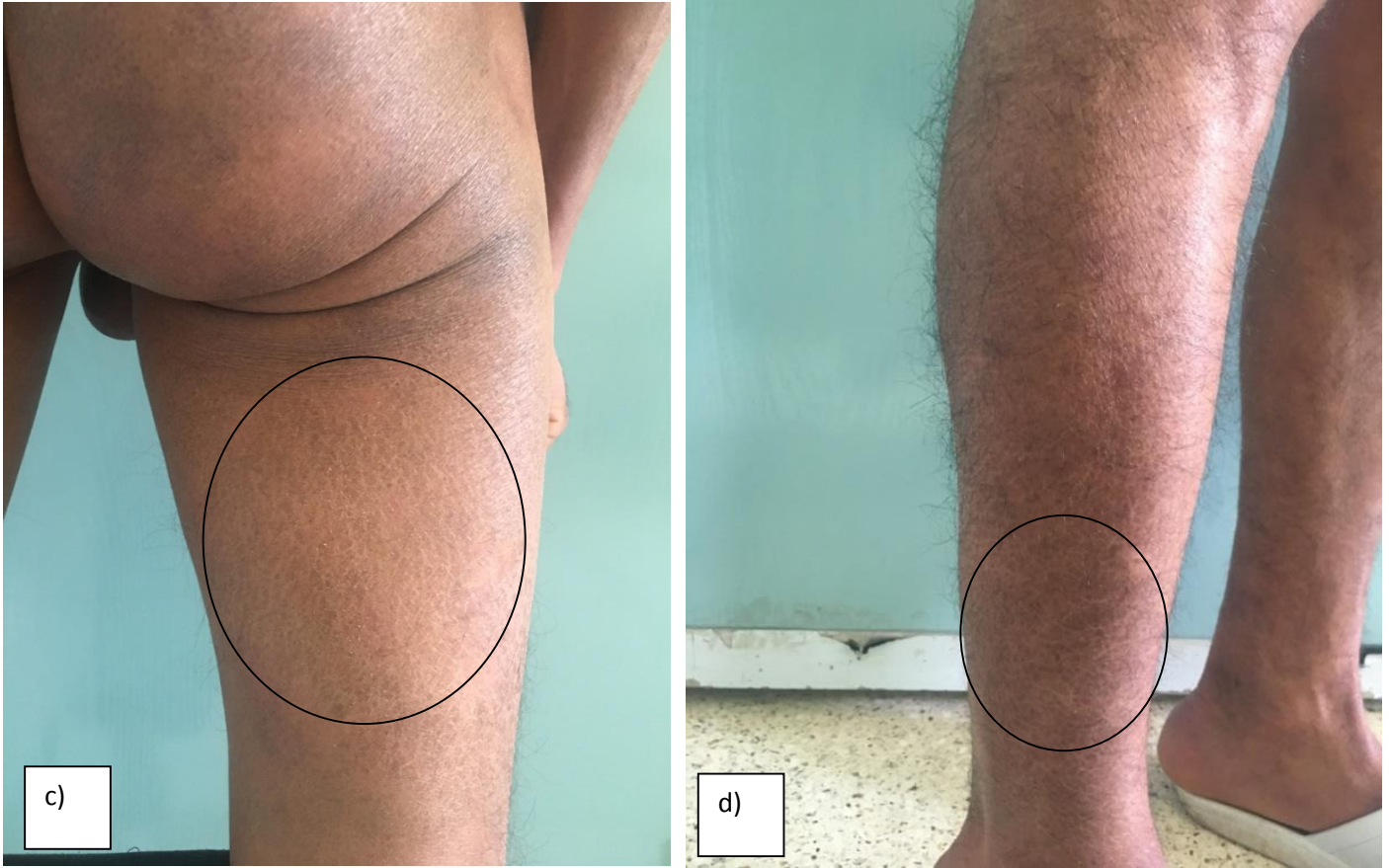
Mycosis fungoides (MF) is the most common form of cutaneous T-cell lymphoma (CTCL) and is characterized by the clonal expansion of skin-homing T lymphocytes. Various clinical and histological variants of MF have been reported .

Ichthyosiform MF (IMF) is not as well-known as other variants of MF. We report here the clinical and histopathological features of patient with IMF.

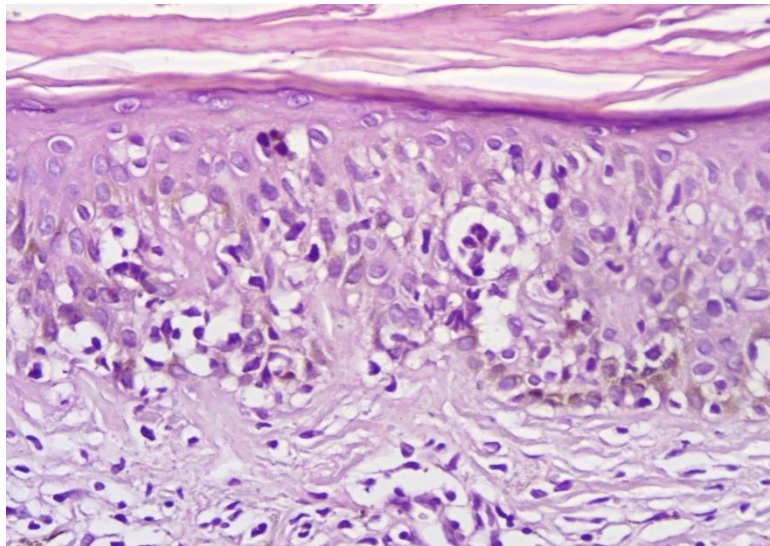
### Case report

A 56-year-old man had consulted for ichthyosiform eruption (figure1) of the lower extremities evolving for 2 years associated with maculopapules discreetly pruritic trunk of more recent appearance and polyadenopathy. Cutaneous biopsy revealed Ichthyosiform mycosis fungoides on lesions of ichthyosis and the appearance of a MF classic on the trunk lesions (figure2). The labeling of lymphocytes was strongly positive for CD3 and CD4 and weakly positive for CD8. There was no histological lymph node involvement. The Thoracoabdominopelvic TDM was normal. The selected diagnosis was that of a stage IIa MF in its classic form on the trunk and the upper limbs and ichthyosiform type on the legs. A methotrexate was indicated in the patient , whose evolution is in progress.





**Figure : 1. a-d :** Ichthyosiform status and particulars of the lesions (circle) on various sites of the body.



**Figure 2 :** The biopsy specimen shows a compact, thick orthokeratosis, a thinned epidermis with a slightly decreased granular layer and an upper dermal mononuclear cell infiltrate with Pautrier's microabscess in the epidermis (H&E,  $\times 200$ ).

## Discussion

Mycosis fungoides (MF) is the most common type of cutaneous T-cell lymphoma (CTCL), and MF is a malignant lymphoma that's characterized by the expansion of a clone of the CD4+ (or helper) memory T cells that frequently lacks other normal T-cell antigens (CD7). It usually begins as flat patches, which may or may not be histologically diagnosed as MF. Many variations of MF have been described, such as the follicular, granulomatous, hypo- or hyperpigmented and unilesional variants 1-2. Moreover, ichthyosis-like eruption may very rarely be the first sign of MF. A few cases have recently been reported in which the ichthyosiform eruption proved to be a specific manifestation of MF (3-4). Ichthyosiform MF differs from acquired ichthyosis associated with cutaneous lymphoma. Aram first reported ichthyosiform lesions as a clinical manifestation of MF (5).

Ichthyosiform states are rarely associated with cutaneous lymphomas. Isolated, they would often suggest first the paraneoplastic hypothesis. In the particular situation of MF, ichthyosiform eruption may also in rare cases, like that of our patient, correspond to a particular entity : MF ichthyosiform. This new, rare variant of MF is defined by a clinical aspect suggestive of ichthyosis vulgaris and a histology associating the specific appearance of mycosis fungoides and that of ichthyosis vulgaris. Ichthyosiform MF can be divided into 3 types: 1) ichthyosiform eruption as the sole manifestation of the disease, 2) ichthyosiform eruption in conjunction with additional atypical findings of MF and 3) ichthyosiform eruption in combination with the classic types of MF (6). Marzano et al. and Hodak et al. are the previous studies have reported IMF accompanied by classical MF or follicular MF (7, 8), but there have been no reports of IMF accompanied by primary cutaneous anaplastic large cell lymphoma. Our patient had the ichthyosiform eruption in combination with the hypo- or hyperpigmented types of MF. Ichthyosiform MF has similar histopathologic findings to classic MF combined with features of ichthyosis, such as hypogranulosis and hyperkeratosis. The detection of features from both entities in the same biopsy specimen narrows the

differential diagnosis down to ichthyosiform MF and paraneoplastic ichthyosis in a patient with known MF (8).

## Conclusion

IMF can be considered as a rare type of early MF with a comparatively favorable prognosis, which is common in young patients. When examining patients with ichthyosiform lesions, careful evaluation including skin biopsy is necessary to rule out the possibility of IMF.

## Références

1. Kazakov DV, Burg G, Kempf W (2004) Clinicopathological spectrum of mycosis fungoides. *J Eur Acad Dermatol Venereol*; 18:397-415.
2. Lacour JP, Castanet J, Perrin C, Ortonne JP (1993) Follicular mycosis fungoides: A clinical and histologic variant of cutaneous T-cell lymphoma: Report of two cases. *J Am Acad Dermatol*; 29:330-334
3. Bianchi L, Papoutsaki M, Orlandi A, Citarella L, Chimenti S (2007) Ichthyosiform mycosis fungoides: a neoplastic acquired ichthyosis. *Acta Derm Venereol*; 87:82-83.
4. Kütting B, Metze D, Luger TA, Bonsmann G (1996) Mycosis fungoides presenting as an acquired ichthyosis. *J Am Acad Dermatol*; 34:887-889.
5. Aram H (1984) Acquired ichthyosis and related conditions. *Int J Dermatol* ; 23: 458-461.
6. Kütting B, Metze D, Luger TA, Bonsmann G (1996) Mycosis fungoides presented as an acquired ichthyosis. *J Am Acad Dermatol*; 34:887- 889.
7. Hodak E, Amitay I, Feinmesser M, Aviram A, David M (2004) Ichthyosiform mycosis fungoides: an atypical variant of cutaneous T-cell lymphoma. *J Am Acad Dermatol*; 50: 368-374.
8. Marzano AV, Borghi A, Facchetti M, Alessi E (2002) Ichthyosiform mycosis fungoides. *Dermatology*; 204: 124-129.



This work is licensed under Creative Commons Attribution 4.0 License

To Submit Your Article Click Here: [Submit Manuscript](#)

DOI: [10.31579/2690-1919/030](https://doi.org/10.31579/2690-1919/030)

### Ready to submit your research? Choose Auctores and benefit from:

- ❖ fast, convenient online submission
- ❖ rigorous peer review by experienced research in your field
- ❖ rapid publication on acceptance
- ❖ authors retain copyrights
- ❖ unique DOI for all articles
- ❖ immediate, unrestricted online access

At Auctores, research is always in progress.

Learn more [www.auctoresonline.org/journals/journal-of-clinical-research-and-reports](http://www.auctoresonline.org/journals/journal-of-clinical-research-and-reports)