

# Acute Retinal Necrosis A Potentially Visual Devastating Affection

Nawal Khanaouchi \* A.khoyali, R.zerrouk, Y.Mouzarii, K.Redha and A.Oubaaz

Department of Ophthalmology, Military Instruction Hospital Mohammed V, Rabat, Morocco

\*Corresponding Author: Nawal Khanaouchi, Department of Ophthalmology, Military Instruction Hospital Mohammed V, Rabat, Morocco.

Received date: August 12, 2021; Accepted date: August 31, 2021; Published date: September 14, 2021

Citation: Nawal Khanaouchi, A.khoyali, R.zerrouk, Y.Mouzarii, K.Redha, A.Oubaaz (2021). Acute Retinal Necrosis A Potentially Visual Devastating Affection. *Experimental and Clinical Ophthalmology*. 1(1). DOI: [10.31579/ECO.2021/004](https://doi.org/10.31579/ECO.2021/004)

Copyright: © 2021 Nawal Khanaouchi This is an open access article distributed under the Creative Commons Attribution License, which permits unrestricted use, distribution, and reproduction in any medium, provided the original work is properly cited.

## Abstract

Acute retinal necrosis syndrome (ARN syndrome) is a rare condition, caused by DNA viruses. The diagnosis of this condition is mainly based on the suggestive clinical appearance. Prompt diagnosis and treatment are crucial to prevent visual loss. We report the case of a 56-year-old woman, diabetic, who presented to the emergency room for rapid decrease of visual function of her left eye which revealed granulomatous uveitis with retinal necrosis.

**Keywords:** ARN syndrome; granulomatous uveitis; visual loss; vitritis; diabetic

## Introduction

Described firstly in 1971 by Uryama et al. The acute retinal necrosis syndrome (ARN syndrome) is a rare condition, caused by DNA viruses mainly Varicella zoster virus (VZV) and Herpes simplex virus type (1 and 2), cytomegalovirus (CMV) is less common. The diagnosis is mainly based on the suggestive clinical appearance. The institution of antiviral therapy should not be delayed. Prompt diagnosis and treatment are crucial to salvage vision in this frequently blinding condition and preventing involvement of the fellow eye.

The prognosis remains poor due to the extension of retinal necrosis and the risk of retinal detachment in an area of retinal atrophy.

## Clinical Case

We report the case of a 56-year-old woman, diabetic, who presented to the emergency room for rapidly progressive loss of vision of her left eye,

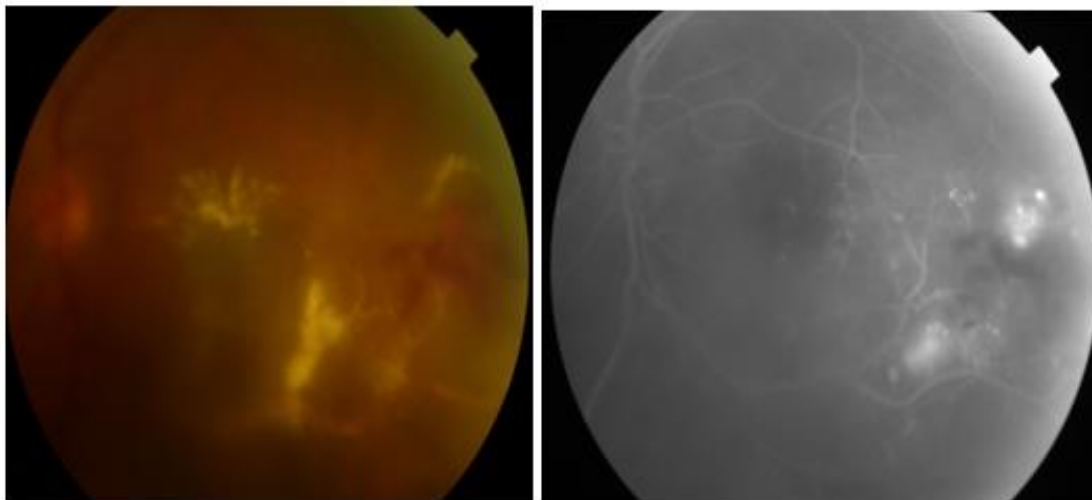
associated with redness and ocular pain evolving, for 10 days with worsening of symptoms since 3 days.

The visual acuity at admission was at counting fingers; slit lamp examination showed granulomatous retro-desmetic opacities with + 3 cells in the anterior chamber, IOP at 18 mm Hg in the OS.

The fundus examination of the left eye, revealed severe vitritis, associated with necrotic-hemorrhagic patches, and cystoid vasculitis and macular edema.

On The right eye visual acuity, was up to 20/20, the slit lamp exam of this eye was unremarkable.

Angiography showed the presence of occlusive vasculitis and perimacular patches of retinitis, associated with macular edema. **Figure 1**



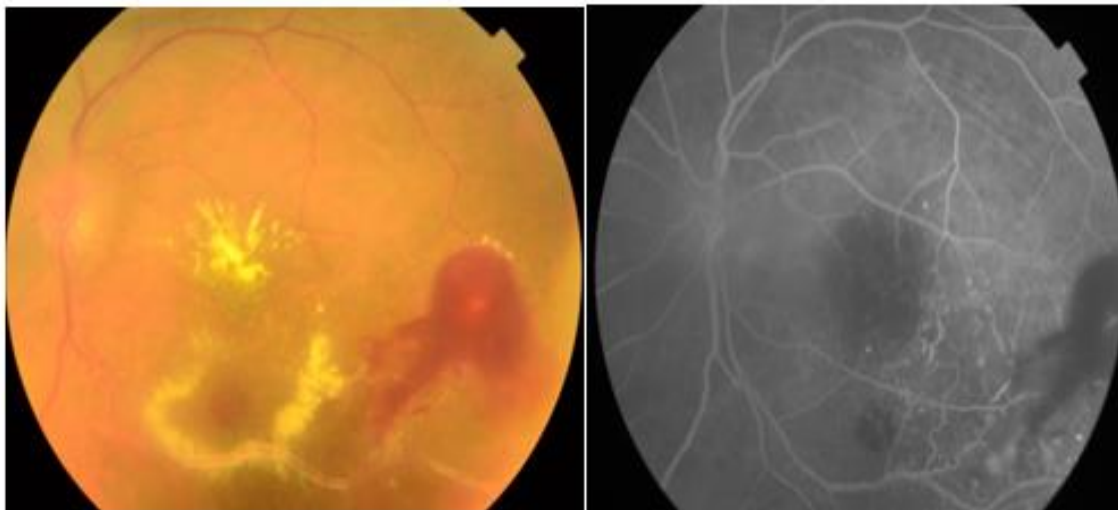
**Figure 1:** Acute retinal necrosis with severe vitritis and macular edema before treatment .

In view of the clinical aspect, an acute viral retinal necrosis was suspected, and an intra venous antiviral-based treatment was started urgently with aciclovir at a dose of 10mg / kg / 8h followed 48h later by a bolus of methylprednisolone at a dose of 500mg per day for 3 days.

Simultaneously a Polymerase chain reaction of the aqueous tap was done and it turn positive for HSV-1 and negative for HSV-2, Varicella Zoster

Virus (VZV) and Cytomegalovirus (CMV).the diagnosis of viral retinitis was made.

The evolution was marked by the disappearance of inflammatory reaction in the anterior chamber, a manifest decrease of vitritis after 3 days of treatment. After 1 month of treatment, the visual acuity of the left eye is limited to 20/200, with a calm anterior segment and regression of perivascular sheath as well as macular edema. **Figure 2**



**Figure 2:** Manifest Improvement after antiviral treatment, disappearance of vitritis and regression of perivascular inflammation, although we notice the presence of perimacular ischemic zones with Micro-vascular angiopathy and neovascularization.

The patient is currently on antiviral treatment taking oral prophylactic dose, oral corticosteroids in decreasing dose and IVT antiangiogenics due to the presence of an area of central ischemia complicated by neovascularization not accessible to PRP.

### Discussion

ARN syndrome is clinically defined by the presence of the classic triad associating full-thickness retinal necrosis of yellowish white appearance with peripheral location and well-limited edges, vasculitis and more or less severe vitritis. Other clinical manifestations may be indicative of this condition such as inflammation of the anterior segment complicated by ocular hypertonia, macular or papillary edema.

In decreasing order of the pathogens involved in ARN syndrome we find, varicella zoster virus in more than half of cases, followed by herpes simplex virus (HSV), and then less frequently the Epstein-Barr virus. CMV-linked ARN syndrome remains very rare [1].

It affects both sexes with a slight male predominance, without preferential age, however two frequency peaks, were found, around 20 and 50 years old, related for the first to an attack by herpes simplex and for the second peak a varicella- zoster infection. And it is often found in immunocompetent individuals [1, 2].

The mechanism of retinal infection is probably R.eactivation in the central nervous system from a latent site of infection.

The main risk factor is a history of viral infections regardless of its location [3].

Several series have suggested a high prevalence of viral retinitis on a ground of genetic susceptibility. Holland and colleagues, have demonstrated high prevalence of HLA-DQw7 antigen in patients with RNA syndrome than in the normal population, other genetic phenotypes one was highlighted such as Bw62, DR4 [1, 4]

ARN syndrome is classically revealed by a rapidly progressive visual impairment, most often unilateral, associated with redness, eye pain and myodesopsia.

Examination of the anterior segment may reveal granulomalous anterior uveitis, hypertonia, and inflammatory reaction in the anterior chamber. Sometimes papillary and macular edema is associated to the retinal necrosis on fundus.

The diagnosis of this affection, is made on clinical presumption, no assessment should delay urgent treatment. Moreover, the detection of viral DNA by PCR technique, in aqueous humor or vitreous specimen is particularly interesting. Indeed PCR is very sensitive (80 to 96%) and requires only a small amount of sampling [2].

Viral necrotizing retinitis can be confused with various ocular involvement including extensive toxoplasmic retinitis, syphilis, endophthalmitis of parasitic origin, ocular lymphoma and necrotizing retinitis in the context of behcet's disease, therefore an initial complete assessment is crucial without delaying the urgent therapeutique process.

The goal of treatment is to stop viral multiplication and the extention of the retinal necrosis as well as inflammation, it is based essentially on intra-veinous antiviral associated with anti-inflammatory and antithrombotic treatment depending on virus isolated.

Acyclovir should be started at 10-13 mg/kg every 8 hours or 1500mg/m<sup>2</sup>/day intravenously (IV) for 5-10 days. This should be followed by acyclovir 800 mg five times daily orally for 6 weeks to 3 months. Some studies suggest oral therapy at beginning such as

Valacyclovir given at a dose of 1000-2000 mg orally every 8 hours. This has good bioavailability and avoids the need for intravenous access [5].

A long term oral antiviral treatment is required to prevent recurrence. The visual prognostic is generally poor, severe complications may occur , such as retinal detachment , optic neuropathy and ischemic vasculopathy involving the macula can cause severe visual loss .

## Conclusion

To conclude ARN is a rare but potentially visually threatening condition that can lead to blindness. First line therapy is intra-venous antiviral treatment, relayed by oral therapy to prevent recurrences. However, the cost of therapy is high and patient compliance can be a problem especially in developing countries which make the prognosis of this affection more fatal in these cases.

## References

1. Avrey Thau, Lauren Taney, MD, Murtaza Adam, MD. Acute Retinal Necrosis. American Academy of Ophthalmology.
2. Izambart, C., Zur, C., Fiandrino, P., Tieulie, N., Cassoux, N., & Gastaud, P. (2009). Management of acute retinal necrosis syndrome complicated by cystoid macular edema. French Journal of Ophthalmology, 32(1), 60.e1–60.e6.
3. Holland, G. N., Cornell, P. J., Park, M. S., Barbetti, B., Yuge, J., Kreiger, A. E., Kaplan, H. J., Pepose, J. S., Heckenlively, J. R., Culbertson, W. W., and Terisaki, P. I.: An association between acute retinal necrosis syndrome and HLA-DQw7 and phenotype Bw62, DR4. Am. J. Ophthalmol. 108:370, 1989.
4. Jennifer I Lim MD, Koushik Tripathy, MD (AIIMS), FRCS (Glasgow), Lauren Taney, MD, Murtaza Adam, MD, Vinay A. Shah M.D. and Vinay A. Shah M.D. Acute retinal necrosis.
5. Bergstrom R, Tripathy K. Acute Retinal Necrosis. [Updated 2021 Jul 4]. In: StatPearls [Internet]. Treasure Island (FL): StatPearls Publishing; 2021 Jan.



This work is licensed under Creative Commons Attribution 4.0 License

To Submit Your Article Click Here: [Submit Manuscript](#)

DOI: [10.31579/ECO.2021/004](https://doi.org/10.31579/ECO.2021/004)

### Ready to submit your research? Choose Auctores and benefit from:

- ★ fast, convenient online submission
- ★ rigorous peer review by experienced research in your field
- ★ rapid publication on acceptance
- ★ authors retain copyrights
- ★ unique DOI for all articles
- ★ immediate, unrestricted online access

At Auctores, research is always in progress.

Learn more [auctoresonline.org/journals/new-medical-innovations-and-research](https://auctoresonline.org/journals/new-medical-innovations-and-research)