

A Case Report of Cortisol-Secreting Adrenal Adenoma Causing Cushing Syndrome

Husain Taha Radhi ^{1*}, Rawdha Fardan ², Aysha Asif Sarwani ³, Eman Al Juffairi ⁴, Riyadh Almerbati ⁵ and Hasan Farrokh ⁶

¹ Department of Endocrinology, Salmaniya Medical Complex, Ministry of Health, Bahrain.

² Department of Internal Medicine, Salmaniya Medical Complex, Manama, Bahrain.

³ Department of Internal Medicine, Salmaniya Medical Complex, Manama, Bahrain.

⁴ Department of Pathology, Salmaniya Medical Complex, Manama, Bahrain.

⁵ Department of Internal Medicine, Salmaniya Medical Complex, Manama, Bahrain.

⁶ Department of Internal Medicine, Salmaniya Medical Complex, Manama, Bahrain.

***Corresponding Author:** Husain Taha Radhi, Department of Endocrinology, Salmaniya Medical Complex, Ministry of Health, Bahrain.

E-Mail: husaintaha74@yahoo.com

Received date: September 23, 2019; **Accepted date:** October 09, 2019; **Published date:** October 14, 2019

Citation: Husain TR., Rawdha F., Aysha AS., Eman AJ., Riyadh A., and Hasan FA., (2019) Case Report of Cortisol-Secreting Adrenal Adenoma Causing Cushing Syndrome. J Endocrinology and Disorders. 3(1): Doi: [10.31579/2640-1045/044](https://doi.org/10.31579/2640-1045/044)

Copyright: © 2019 Husain TR. This is an open-access article distributed under the terms of the Creative Commons Attribution License, which permits unrestricted use, distribution, and reproduction in any medium, provided the original author and source are credited.

Abstract

Cushing syndrome is a state of prolonged exposure to excess cortisol production. Causes can be varied ranging from exogenous intake or endogenous production from a pituitary source due to overproduction of adrenocorticotropic hormone (ACTH) or due to over secretion from unilateral or bilateral adrenal glands.

Cushing syndrome in an adult can present with proximal muscle weakness, facial plethora, wasting of the extremities with increased fat in the abdomen and face, wide purplish striae, bruising with no obvious trauma, and supraclavicular fat pads.

Here, we report a 38 year old male who presented with suspicion of having Cushing syndrome due to his clinical manifestations and high cortisol levels. He presented to the clinic with new onset diabetes, severe hypertension, chronic abdominal pain and distension which was being investigated by different specialties. The patient underwent CT scan of the abdomen which show right adrenal adenoma and on examination, he was found to have proximal weakness and purple striae. Laboratory data showed high morning cortisol, 24 urine free cortisol and ACTH levels which were strongly suggestive of ACTH independent Cushing syndrome.

Key words: Cushing syndrome; Adrenal Adenoma; hypercortisolism

Introduction

Cushing syndrome is a condition resulting from chronic overproduction of glucocorticoid (1) therefore the signs and symptoms depend on the duration and intensity of excess steroid production (2) which lead to multisystem manifestations due to overproduction of the hormone.

The clinical manifestations can be categorized as reproductive, dermatologic, metabolic, cardiovascular, musculoskeletal, neuropsychiatric, and infectious (3-5). In addition to the considerable morbidity caused by hypercortisolism, there is also an increase in mortality rates.

The source of increased glucocorticoids can be exogenous due to chronic administration of corticosteroids for any underlying inflammatory condition or endogenous source which can be ACTH dependent or ACTH independent (6).

Pituitary ACTH-dependent Cushing's disease is five to six times more common than Cushing's syndrome caused by benign and malignant adrenal tumours combined (7). Thus, the incidence of Cushing's disease may be 5 to 25 per million per year. However, the reported incidences was much lower (1.2 to 2.4 per million per year) in one population-based study (8, 9). In a United States study, the incidences were higher than

previously reported in European studies as it was found to affect 6.2 to 7.6 per million person-years (10).

Cushing syndrome due to adrenal adenoma is rare condition, but it is associated with high mortality rates if left untreated particularly from cardiovascular disease (3). However, median survival from cures was still excellent according to (cohort study) of patients who had been cured of hypercortisolism for at least 10 years at study (11).

Case Report

A 38-year-old male attended the endocrine clinic with history of chronic abdominal pain, recent onset Diabetes Mellitus and severe uncontrolled hypertension despite being on treatment (Table 4).

Patient had previously visited several clinics and hospitals with the complaint of abdominal pain and distension which had been present for 3 years. His symptoms also included chronic fatigue, acne and the findings on the clinical examination demonstrated central obesity, proximal weakness, moon face, plethora, skin thinning, fat pads and purple striae (Figure 5-12).

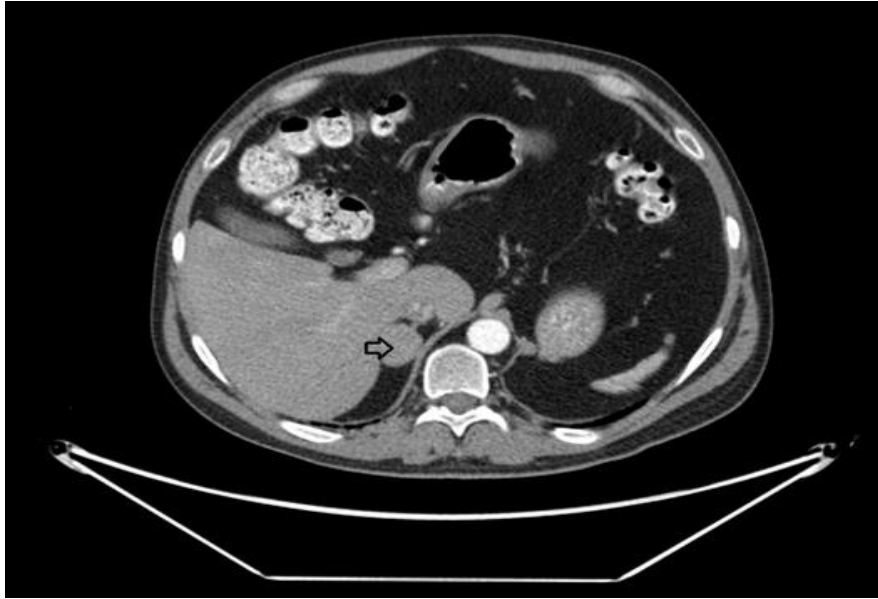


Figure 1: Axial cut of abdominal CT shows intermediate right adrenal nodule (arrow).

A CT scan of the abdomen was performed (Figure 1) along with whole body F18 FDG Pet/CT scan and it showed the right adrenal adenoma measuring 27x23 mm. (Figure 2).

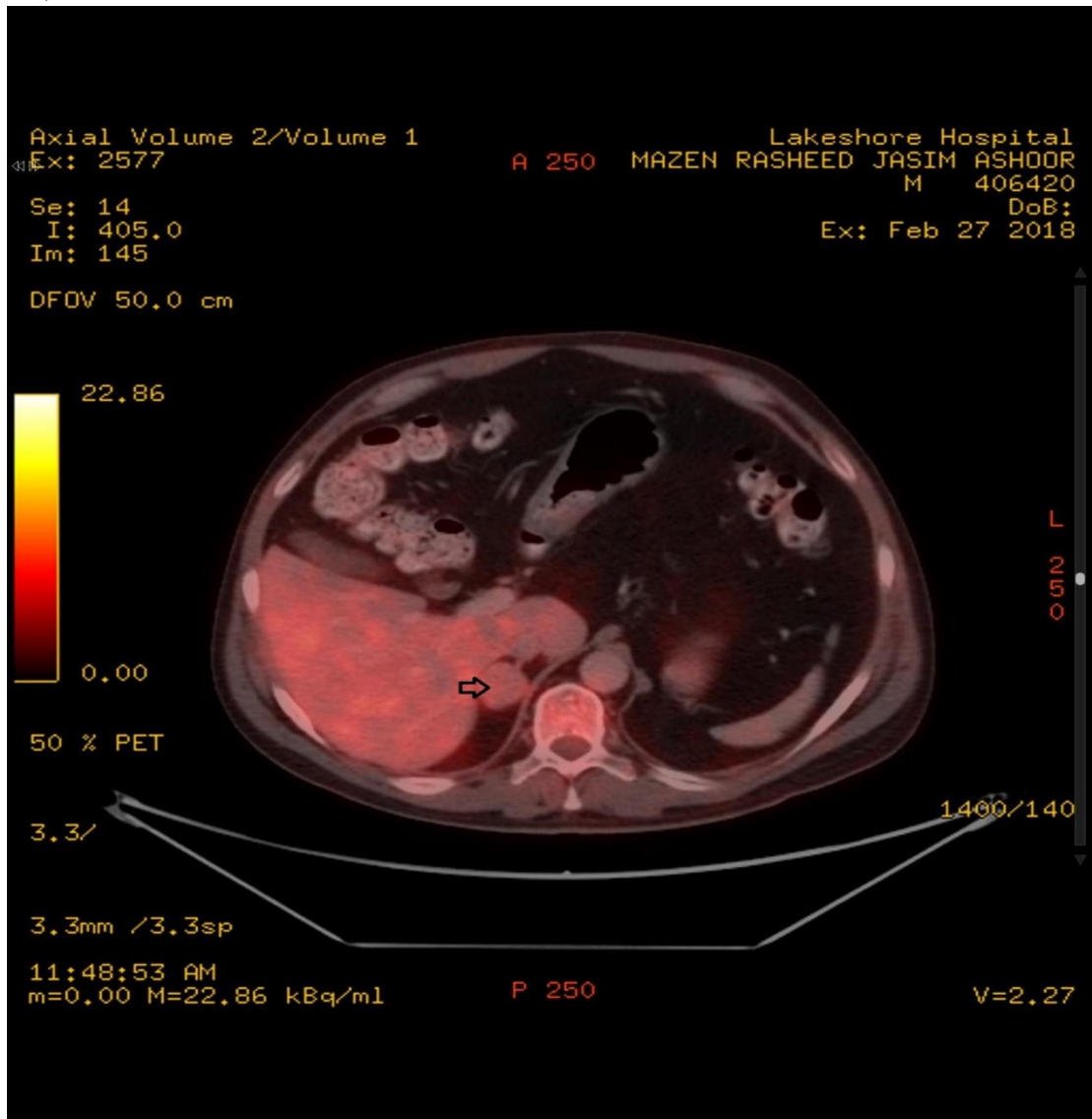


Figure 2: Whole body PET scan (vertex to mid-thigh) with contrast (oral and intravenous) enhanced CT was performed using a dedicated Discovery IQ PET 16 slice CT scanner 60 minutes after i.v. injection of 7 mCi of F-FDG. The blood glucose level was 115 mg/dl before the injection. The standardized uptake value (SUV) was calculated based in body weight and expressed in g/ml. There is an FDG negative well defined mildly enhancing soft tissue nodule measuring 27 x 23mm in the medial limb of right adrenal gland (arrow).

Extensive workup was done to investigate the adenoma for assessment of a functional tumor evaluating for Primary hyperaldosteronism (Table 1), Pheochromocytoma (Table 2), Cushing disease or any other condition.

Variable	Result	Normal Ranges
ACTH	5 pg/ml	10-48
Aldosterone	6.5 ng/dl	1.2-24
Renin	19.7 ng/dl	2.6-28
Aldosterone/Renin Ratio	3.3	< 19

Table 1: Biochemical results of Renin/Aldosterone

Variable	Result	Normal Ranges
Catecholamine	<50 ng/l	<90
Metanephrine	< 50 ng/l	<90
Normetanephrine	96 ng/l	<129
Adrenaline	< 20	Up to 82
Noradrenaline	388	Up to 499
Dopamine	< 20	Up to 58

Table 2: Biochemical result of catecholamine and Metanephrine
Confirmatory tests for Cushing syndrome came positive for cortisol 8 AM and 24 hour urinary free cortisol, supporting the diagnosis of Cushing syndrome (Table 3) and a low ACTH value excluding Cushing disease (Table 1).

Variable	Result	Normal Ranges
Urine volume	1600 ml	
Urine cortisol	534 mcg/24h	21-292
Cortisol 8am	1000 nmol/l	65-635

Table 3: Biochemical result of 24 hour free cortisol and cortisol 8 AM

Further investigation was requested to evaluate for the complications secondary to the disease including echocardiography and renal Doppler study, both of which were normal. His vitals were checked during his visits to the clinic and documented for high blood pressure (Table 4).

Heig ht	Weig ht	Tem p.	R R	Puls e	BP	BM I	BS A	SPO 2
166 cm	72kg	36.2	18	100	182/1 24	26.1 3	1.8	99%

Table 4: Pre-operative vitals at the time of diagnosis

Metabolic panel was done as baseline for his condition (Table 5) which confirmed the new onset Diabetes mellitus and hyperlipidemia as well which are considered as part of his primary disease.

Variable	Result	Normal Ranges
Sodium	136 mmol/l	136-145
Potassium	5 mmol/l	3.5-5.1
Chloride	98 mmol/l	96-106
Bicarbonate	27.9mmol/l	24-30
Creatinine	84 umol/l	62-140
Calcium	2.6 mmol/l	2.1-2.6
Cholesterol	7.2 mmol/l	3.6-5.2
HDL	1.25 mmol/l	0.8-1.8

Variable	Result	Normal Ranges
LDL	3.7 mmol/l	1.6-4.7
Triglyceride	2.3 mmol/l	0.2-1.8
AST	24 u/l	8-40
ALT	51 u/l	10-40
Alkaline Phosphatase	172 u/l	40-137
GGT	136 u/l	11-49
PTH	70pg/ml	15-65
HbA1C	8.4	

Table 5: Basic metabolic panel as base line

Based on the results of investigations done for the patient, the diagnosis of Cushing syndrome secondary to adrenal adenoma was confirmed clinically and biochemically supporting the CT and the MRI findings (Image 3, 4). So patient was referred for surgical removal of the functional adrenal adenoma for definitive treatment.

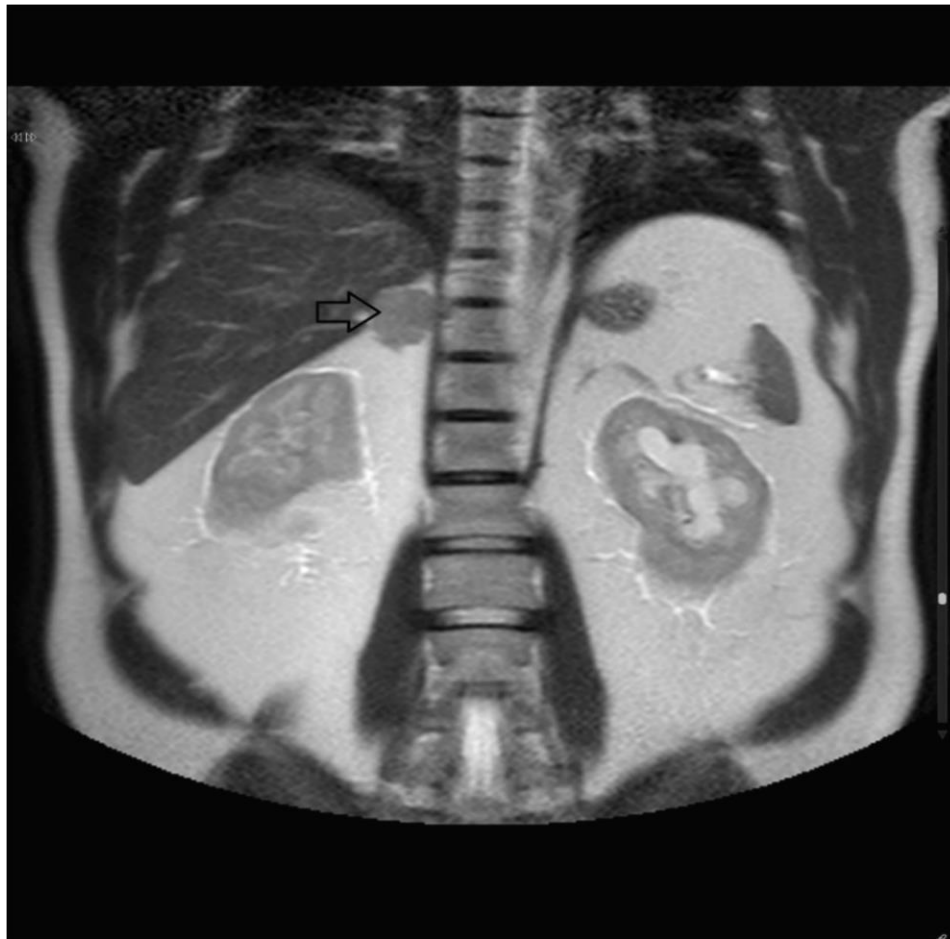

Figure 3: T2 coronal image of MRI abdomen shows a soft tissue lesion in the right adrenal gland consistent with right adrenal adenoma (arrow). Patient underwent laparoscopic excision of the Right adrenal adenoma.

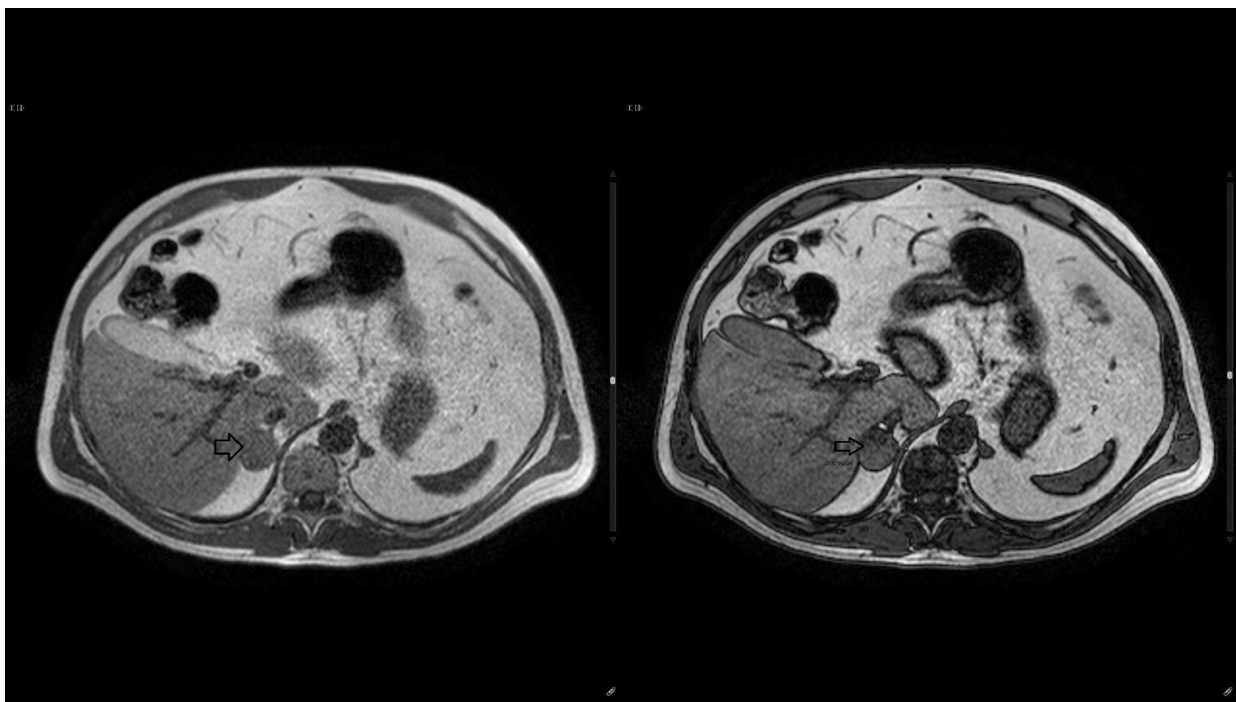


Figure 4 a & b: 2.2 x 2.6 x 2.8 cm (W X AP X CC) well defined intermediate signal lesion in inphase and T2W sequences with no signal suppression in outphase images seen at the body of Rt. Adrenal body suggestive of adrenocortical tumor or adenoma.

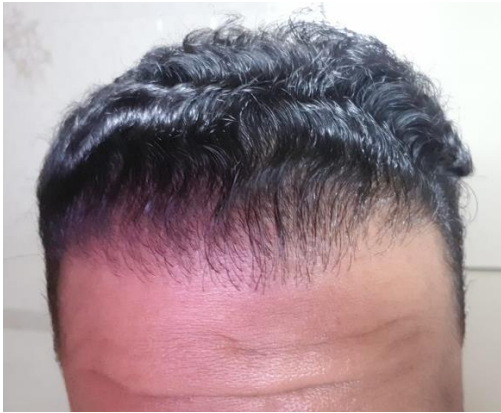

Figure 5: Hair thinning at the time of diagnosis

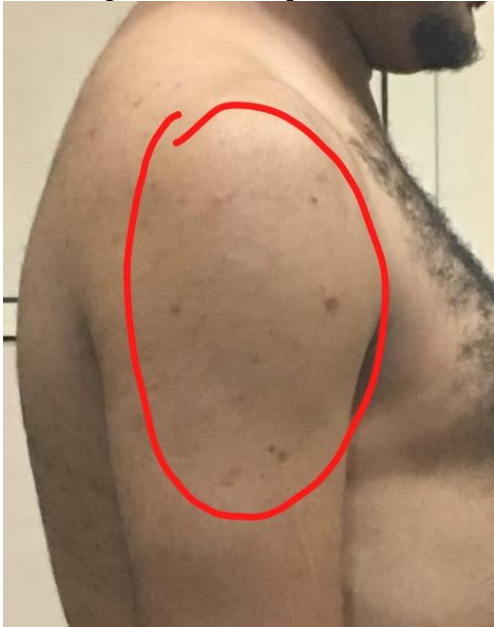

Figure 6: Generalized acne at the time of diagnosis

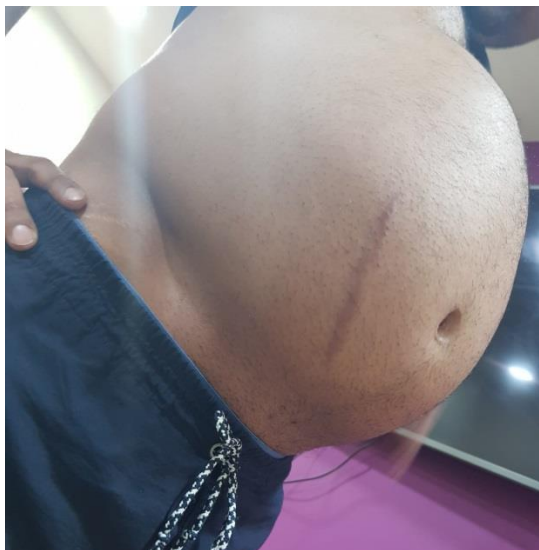

Figure 7: Truncal obesity at the time of diagnosis with purple striae.



Figure 8: Round moon face with hair thinning at the time of diagnosis.



Figure 9: Before the developing the symptoms of Cushing syndrome, the patient had a flat torso.

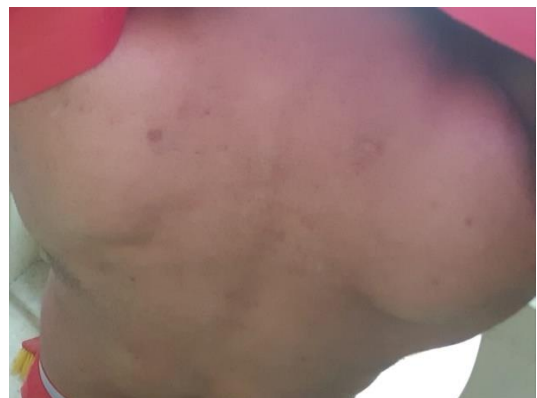

Figure 10: Dorsal Pad of fat prior to operation

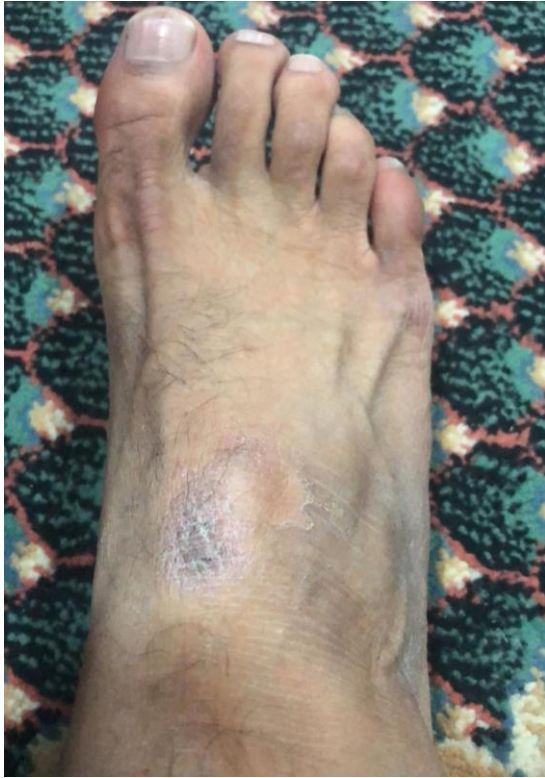

Figure 11: Skin thinning with ulcers at the time of diagnosis.

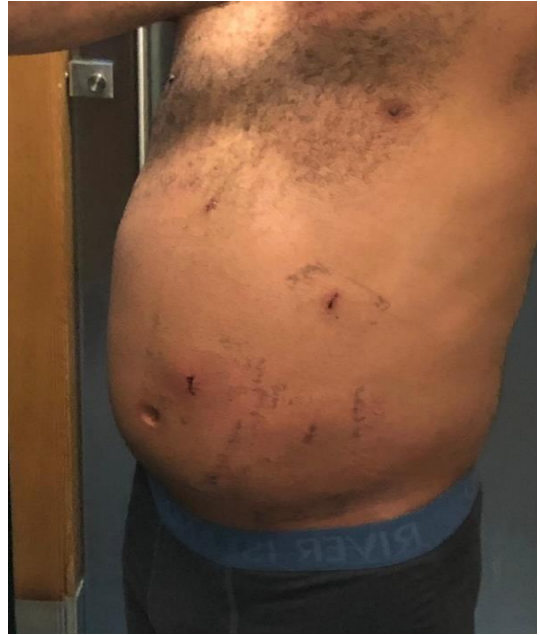

Figure 12: The post-operative of the patient show reduction in central obesity.

Histopathology

Histopathology showed encapsulated adrenal cortical adenoma composed of closely packed nests of polygonal cells with vacuolated eosinophilic cytoplasm and central small nuclei (Figure 13 -14).

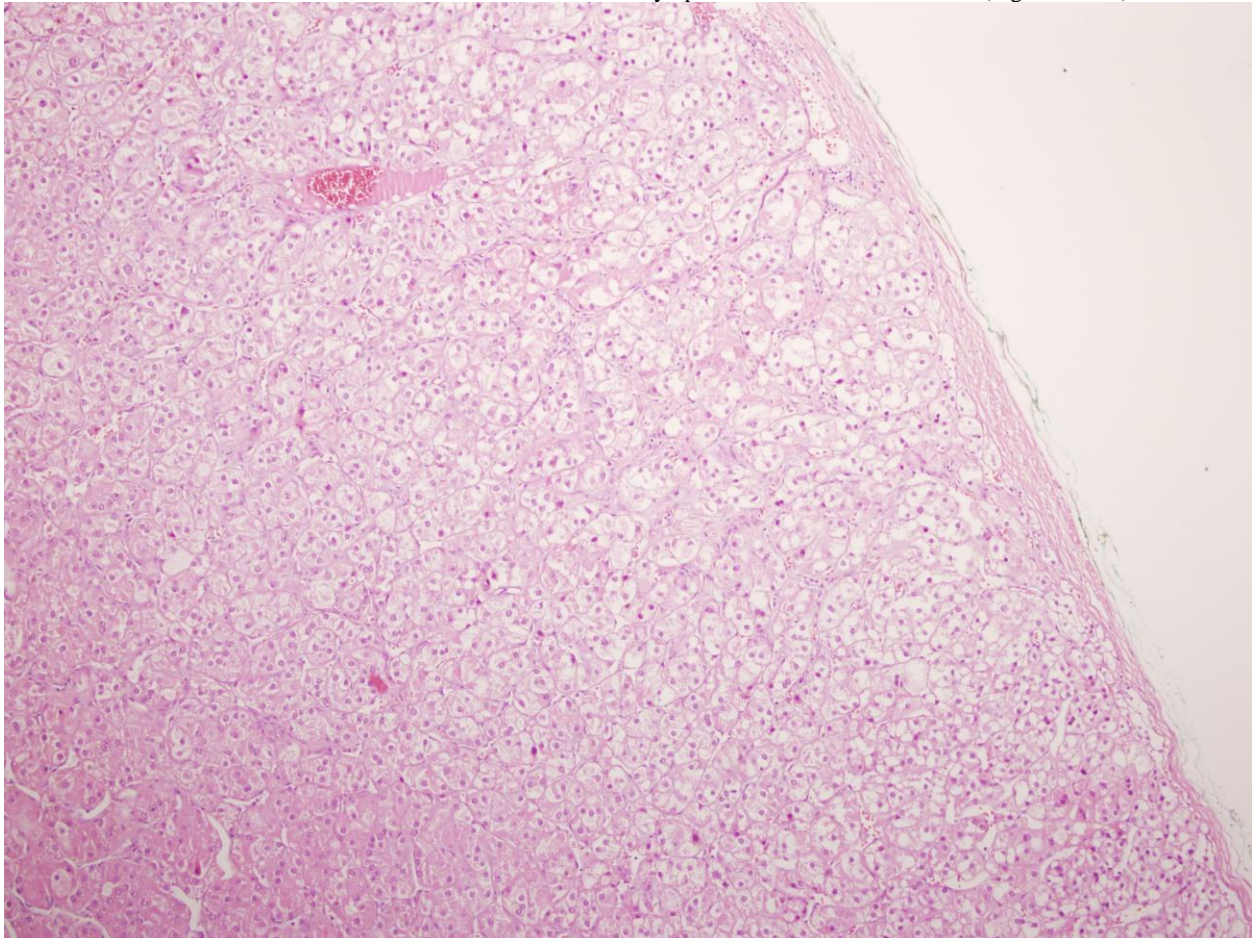


Figure 13: Section shows encapsulated cortical adenoma composed of nests of lipid-rich cells. (Hematoxylin & Eosin stain x100).

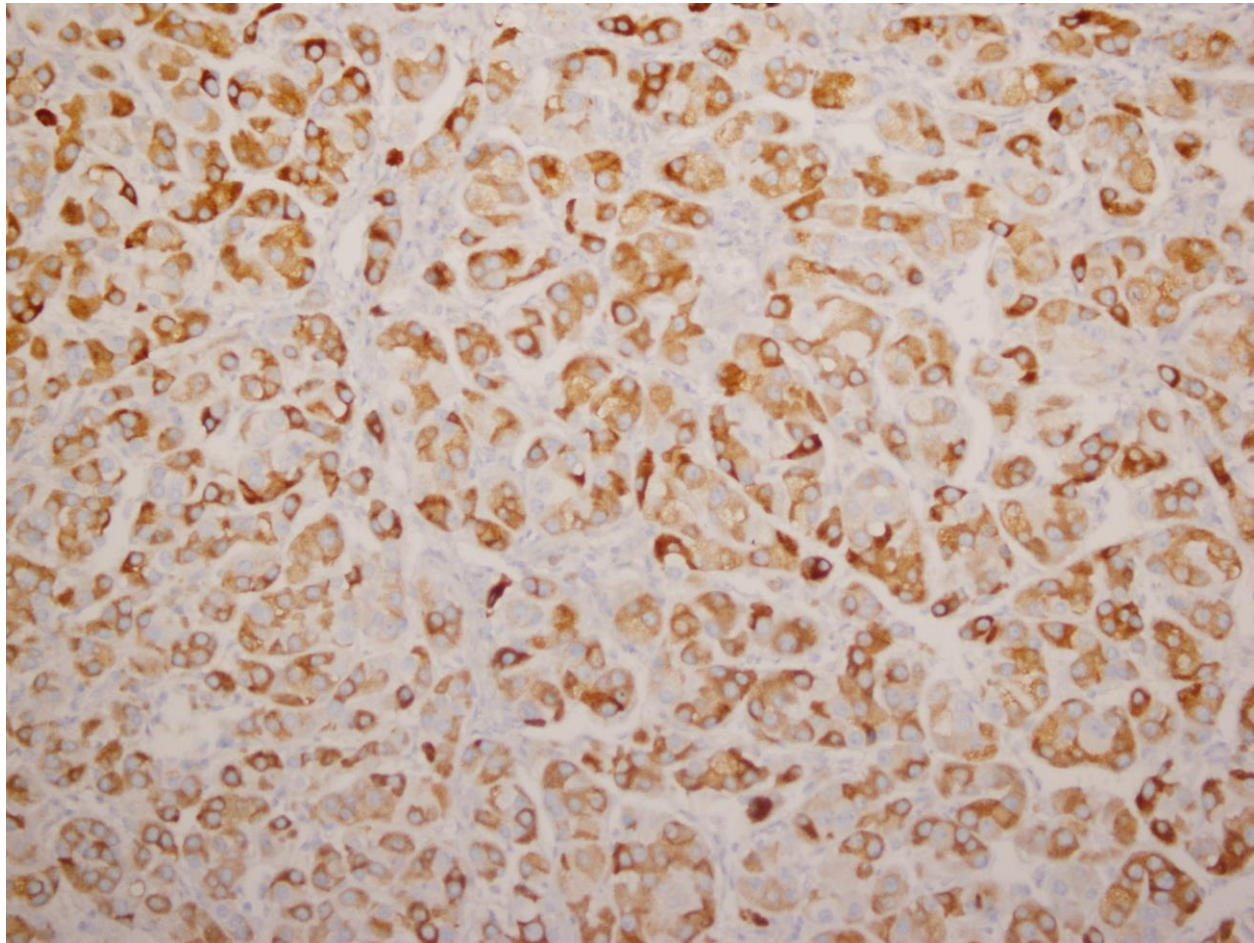


Figure 14 A: By immunostains, the tumour is positive for inhibin (immunostains x100)

No capsular, sinusoidal or vascular invasion, diffuse architecture, significant pleomorphism, atypical mitotic figure or necrosis was seen and the adjacent adrenal gland tissue is unremarkable. The lesion measured 3cm in diameter on gross examination.

Immunohistochemical studies showed the lesion was positive for Inhibin (Figure 14 A) and Melan A (Figure 14 B), while negative for chromogranin. Proliferation index as estimated by ki67 was less than 1%.

During his post-operative follow up, the patient’s glucose profile improved and he was maintained on Metformin 2gm daily with an HbA1c of 4.4%. His blood pressure was maintained within target by monotherapy with Irbesartan (Table 6) and the patient attained a normal BMI of 23.48 with successful resolution of his symptoms and loss of central obesity.

Height	Weight	Temperature	Respiratory Rate	Pulse	Blood Pressure	BMI	BSA	SPO2
166 cm	64.7 kg	36.2	18	96	135/81	23.48	1.72	97%

Table 6: Post-operative vitals

Discussion

This is a typical case of cortisol secreting adenoma causing Cushing syndrome. The diagnosis is often delayed because Cushing syndrome is frequently masked by its overlapping symptoms with many common medical problems. Like the patient in this case attended many clinics including a gastroenterologist clinic for his abdominal pain and CT was

done for him as part of the work up.

The question here is whether all the incidentaloma’s should be investigated or not. The answer is yes especially with the incidence of increasing Cushing syndrome worldwide and because it is a serious disease with high mortality if left untreated (12). Screening should be initiated in all patients with an incidentally discovered adrenal mass, particularly if the CT imaging density is low (<20 Hounsfield units) although in a recent review that argued the drawbacks of screening (cost, acceptability, and unnecessary procedures) may outweigh the benefits (13).

Recent studies have suggested a much higher prevalence among high-risk patient populations, such as patients with diabetes mellitus (particularly if poorly controlled), hypertension, and early-onset osteoporosis (particularly if with fractures) (14-17). In a study done on two hundred patients with poorly controlled diabetes mellitus (HbA1C >8%) were screened for hypercortisolism and 5.5% were diagnosed with Cushing, mostly of adrenal origin (15).

Hypertension is frequently associated with Cushing syndrome with up to 67% prevalence demonstrated in a recent study (18). It resolved in 55% of the patients after treatment like in this patient, and if left untreated, it is a risk factor for cardiovascular events in association with diabetes and dyslipidemia (18). There may (19) or may not be (20) normalization of the risk factor after curative treatment of Cushing syndrome according as shown by different studies (19, 20).

In conclusion, The Endocrine Society clinical practice guidelines recommend testing for Cushing syndrome in patients with multiple signs

and symptoms compatible with the syndrome and the early recognition of disease can prevent the long-term physical consequences and increased mortality that may occur when the disease is left untreated (21).

Informed Consent: Yes

References

1. Newell-Price J, Bertagna X, Grossman A, Nieman L (2006) Cushing's syndrome. *The Lancet*. 367(9522):1605-1617.
2. Katayama M, Nomura K, Ujihara M (1998) Age-dependent decline in cortisol levels and clinical manifestations in patients with ACTH-independent Cushing's syndrome. *Clin Endocrinol (Oxf)*; 49:311.
3. Ross EJ, Linch DC (1982) Cushing's syndrome--killing disease: discriminatory value of signs and symptoms aiding early diagnosis. *Lancet*. 2:646.
4. Nieman LK, Biller BM, Findling JW (2008) The diagnosis of Cushing's syndrome: an Endocrine Society Clinical Practice Guideline. *J Clin Endocrinol Metab*; 93:1526.
5. Nieman LK (2015) Cushing's syndrome: update on signs, symptoms and biochemical screening. *Eur J Endocrinol*; 173:M33.
6. Hopkins R, Leinung M (2005) Exogenous Cushing's Syndrome and Glucocorticoid Withdrawal. *Endocrinol Metab Clin North Am*. 34(2):371-384.
7. Carpenter PC (1988) Diagnostic evaluation of Cushing's syndrome. *Endocrinol Metab Clin North Am*; 17:445.
8. Lindholm J, Juul S, Jørgensen JO (2001) Incidence and late prognosis of Cushing's syndrome: a population-based study. *J Clin Endocrinol Metab*; 86:117.
9. Etxabe J, Vazquez JA (1994) Morbidity and mortality in Cushing's disease: an epidemiological approach. *Clin Endocrinol (Oxf)*; 40:479.
10. Broder MS, Neary MP, Chang E (2015) Incidence of Cushing's syndrome and Cushing's disease in commercially-insured patients <65 years old in the United States. *Pituitary*; 18:283.
11. Clayton RN, Jones PW, Reulen RC (2016) Mortality in patients with Cushing's disease more than 10 years after remission: a multicentre, multinational, retrospective cohort study. *Lancet Diabetes Endocrinol*; 4:569.
12. Bansal V, Asmar N, Selman W, Arafah B (2015) Pitfalls in the Diagnosis and Management of Cushing's Syndrome. *Neurosurg Focus*.38:1–11
13. Tabarin A, Perez P (2011) Pros and cons of screening for occult Cushing syndrome. *Nat Rev Endocrinol*;7:445–55.
14. Anderson GH Jr, Blakeman N, Streeten DH (1994) The effect of age on prevalence of secondary forms of hypertension in 4429 consecutively referred patients.*JHypertens*;12:609–15.
15. Catargi B, Rigalleau V, Poussin A (2003) Occult Cushing syndrome in type-2 diabetes. *J Clin Endocrinol Metab*; 88:5808–13.
16. Chiodini I, Torlontano M, Scillitani A (2005) Association of subclinical hypercortisolism with type 2 diabetes mellitus: a case–control study in hospitalized patients. *Eur J Endocrinol*;153:837–44.
17. Chiodini I, Mascia ML, Muscarella S (2007) Subclinical hypercortisolism among outpatients referred for osteoporosis. *Ann Intern Med*; 147:541–8.
18. Azzoug S, Rabehi L, Hannachi S, Medjdoubi H, Chentli F (2015) Cushing[apos]s syndrome and hypertension. *Endocrine Abstracts*. 37:29.
19. Hammer G, Tyrrell J, Lamborn K (2004) Transsphenoidal Microsurgery for Cushing's Disease: Initial Outcome and Long-Term Results. *The Journal of Clinical Endocrinology & Metabolism*. 89(12):6348-6357.
20. Clayton R, Raskauskiene D, Reulen R, Jones P (2011) Mortality and Morbidity in Cushing's Disease over 50 Years in Stoke-on-Trent, UK: Audit and Meta-Analysis of Literature. *The Journal of Clinical Endocrinology & Metabolism*. 96(3):632-642.
21. Etxabe J, Vazquez JA (1994) Morbidity and mortality in Cushing disease: an epidemiological approach. *Clin Endocrinol (Oxf)*; 40:479–84.